

A Novel Segmentation and Navigation Tool for Endovascular Stenting of Aortic Aneurysms

M. Feuerstein^a, K. Filippatos^a, O. Kutter^a, E.U. Schirmbeck^b, R. Bauernschmitt^b,
N. Navab^a

^aChair for Computer Aided Medical Procedures (CAMP), Technische Universität München, Germany

^bDepartment of Cardiothoracic Surgery, Deutsches Herzzentrum München, Germany

Abstract. Endovascular stenting is a minimally invasive technique to exclude an aortic aneurysm or dissection from the circulatory system. Currently, there is no technical aid to guide the surgical staff during the intervention, except the default visualization interface provided with the CT scanner and mobile C-arm. The purpose of our proposed system is two-fold: (1) In the planning phase, a modified graph cuts algorithm automatically segments the aorta and aneurysm, so the surgical staff can choose an appropriate type of stent to match the segmented location, length, and diameter of the aneurysm and aorta. (2) During implantation of the stent graft, after a landmark based registration of CT and angiography data, the current position of the stent can be visualized in the 3D CT data set at any time. This will enhance the accuracy of the actions of the surgeon, along with a minimum use of angiography, leading to less radiation exposure and less contrast agent injection.

Keywords: Minimally Invasive Surgery, Endovascular Stenting, Computer Aided Surgery, Segmentation, Navigation

1. Purpose

The implantation of a stent graft, also referred to as endovascular stenting, is a minimally invasive surgical procedure that involves the exclusion of an aneurysm from the circulatory system. This is achieved by the placement of a prosthesis (the stent) that is attached to the aorta above and below the dilatation. The implant is mounted on a catheter, which is introduced from the femoral or iliac artery, until the abdominal or thoracic part of the aorta is reached, depending on the location of the aneurysm [1,2].

In the current clinical workflow, pre-operatively a high-resolution contrasted CT of the patient's circulatory system is acquired. Using the visualization interface provided with CT scanner, the procedure is planned. The exact positions of the aneurysm and the branching vessels of the aorta need to be detected manually. Also the stent type is selected manually, based on measured length of the aneurysm and diameter of aorta. We propose a method to allow the user to select one seed point inside the aorta curvature in order to segment whole aorta and aneurysm inside a high-resolution volume.

Intra-operatively, a mobile fluoroscope is used to support the surgeon in positioning the stent. Under angiography, contrast agent is applied periodically to visualize the blood vessels and the current location of stent. Since resulting X-ray image sequences are not registered to the pre-operative CT data, the high-resolution CT data is currently not used intra-operatively. A navigation purely based on two-dimensional image series leads to inaccuracies in the viewing direction, accompanied by manual re-adjustments of the angle of C-arm and acquisition of additional image series.

For the successful implantation of a single stent graft, 15 to 20 X-ray image series are necessary. For every image series under angiography contrast agent is injected in the circulatory system. This frequent use of C-arm increases radiation exposure for patient as well as surgical staff. Additionally, contrast agent injection can cause adverse effects. We propose a navigation component for visualizing current stent position within pre-operative CT volume at any time. This increases the accuracy of intervention while reducing radiation exposure and contrast agent injection.

2. Methods

2.1. Pre-operative Segmentation

Pre-operatively, we replace major parts of the manual interaction needed for finding the location of both aorta and the aneurysm by our automatic segmentation approach, which follows a hybrid approach. It uses a multi-resolution region growing based segmentation for initialization and a region constrained graph cuts [3] algorithm for the final segmentation.

In order to use the graph cuts for segmentation of a high resolution volume, we need to overcome the high (a) memory usage and (b) execution time of this algorithm. Our approach overcomes these problems by first segmenting the contrasted part of aorta inside a downsampled volume. From a single manually placed seed point, we explore the aorta. The curvature along with the ascending and descending branches of the aorta is segmented by an adaptive region growing algorithm. During the initial segmentation we also compute aorta's 2D boundary regions on each slice. These boundary regions and the initial segmentation results are used for initializing the region constrained graph cuts algorithm. Thus, we avoid the initialization of the graph with too many background voxels.

In the second stage, we use the result of the first stage to compute an initialization for the segmentation of the full resolution volume. The resulting volume is upsampled to its original full resolution and refined by morphological operators. Afterwards, the 2D boundary regions are computed again and organized in spatially overlapping groups of 2D slice regions. Each group is segmented separately. The segmentation result of each group is compounded into the final segmented volume (Fig. 1). Finally, a skeletonization algorithm is applied to the segmented aorta to obtain its centerline.

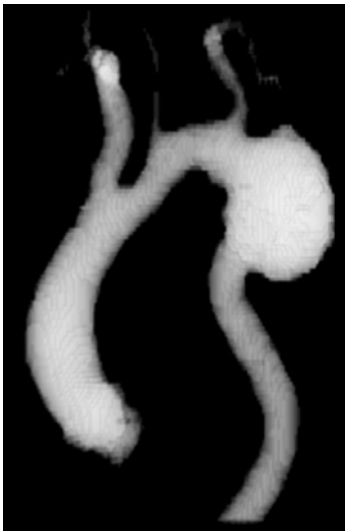


Fig. 1. Segmented aorta and aneurysm.

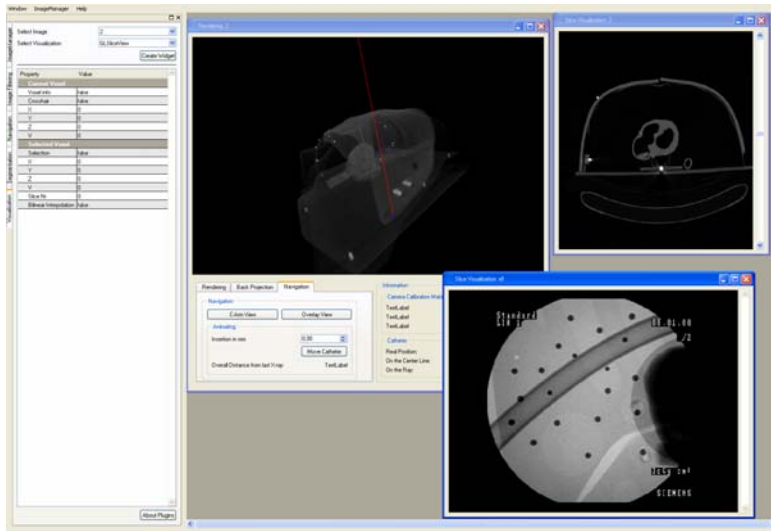


Fig. 2. User Interface of the overall application.

2.2. Intra-operative Navigation

Intra-operatively, we offer an intuitive user interface to visualize the current location of the stent within the three-dimensional volume rendered CT data set (Fig. 2). Therefore, a control X-ray image is acquired and registered with the CT volume. At the same time, the projection geometry of the C-arm is determined online by finding 2D/3D point correspondences of CT spots both visible in the X-ray images and CT volume. The CT spots were pre-operatively adhered to the patient's skin. Their position must not be altered until the intervention or must be clearly marked (e.g. by a felt marker or ink tattoos) to adhere the markers again at the same positions at any later time.

The markers are detected in both the volume and the X-ray image by standard image processing techniques such as thresholding, filling, morphology, and subtraction. The centroids of all segmented markers can be computed very precisely by weighing their associated voxel intensities and incorporating partial volume effects. A distance-weighted graph matching approach is used to find the corresponding markers in the two image modalities. These marker correspondences are used to determine the projection geometry of the C-arm by applying a direct linear transformation (DLT) algorithm [4]. The results describe the C-arm in terms of intrinsic and extrinsic parameters and characterise the X-ray image acquisition process. The obtained transformation aligns the X-ray image and CT volume. Thus, the exact position of the X-ray source and the projection plane of the C-arm can be determined with respect to the CT volume.

To validate the computed projection geometry, the X-ray image can be overlaid by a digitally reconstructed radiograph (DRR) of the 3D volume of the segmented aorta. By means of this overlay the aorta can be made visible on the X-ray image without any further injection of contrast agent (Fig. 3).

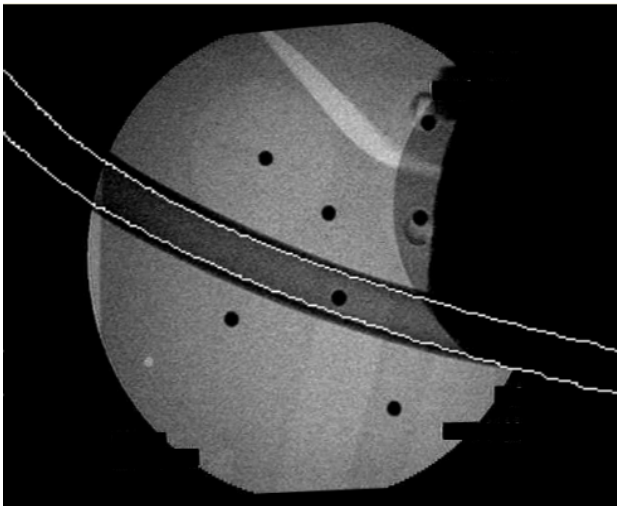


Fig. 3. Overlay of the X-ray image and a DRR of the segmented 3D aorta using phantom data. After post-processing of the DRR only the two white curves remain

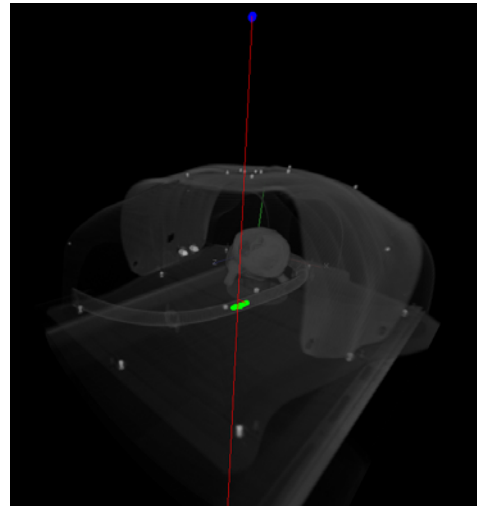


Fig. 4. Volume rendering of the phantom and visualization of the stent. Blue is the camera center, red is the line of sight, and green is the actual position of the stent.

Now the stent's position in the X-ray is marked interactively by the physician. Afterwards, an automatic visualization procedure back projects this 2D position into the 3D volume. A ray (line of sight) can be sent from the X-ray source through the stent's pixel location in the X-ray image. This line defines all visible 3D points in the CT

volume, which are projected onto this pixel. Having the assumption that the stent is always located inside the aorta, we just find the closest point of this line of sight to the centerline of the aorta. This point represents a good approximation for the current position of the stent and allows us to visualize the stent in the CT volume. The stent visualization is based on the length and diameter of the real stent (Fig. 4).

From this point on, the depth of any further insertion or withdrawal of the stent can be determined using a tape measure attached to the catheter. The measured catheter depth is provided to the navigation system by the surgical staff. The stent's current position is immediately visualized by moving it along the aorta's centerline.

3. Results

We implemented a fully functional prototypic system to support both the automatic segmentation of aorta and aneurysms and the intra-operative navigation of a stent graft implantation. The developed segmentation algorithm has been successfully tested on a series of four patients that were treated by endovascular stenting. High-resolution CT data sets with a slice resolution of 512 by 512 pixels and a varying number of slices were used. The navigation system has been evaluated on a phantom of the thorax and the abdomen, containing a tube to represent the aorta and an artificial heart (Fig. 4). 4 mm self-adhesive CT spots were stuck onto the phantom's skin to compute the projection geometry. Additionally, some of them were placed inside the aorta to simulate a stent. They were used as ground truth to validate backprojection accuracy.

4. Conclusion

This paper presents an end-to-end solution for segmentation and navigation for endovascular stenting of aortic aneurysms. Only a single seed point is needed to obtain a fully automatic segmentation of the aorta and the aneurysm. Although we were able to successfully avoid the problem of running out of memory for the aorta segmentation algorithm, we still need to improve the execution time. In a refined implementation one could use multiple processes for the segmentation of the slice groups in parallel in order to speed up the overall process. This speed up is however not crucial because the segmentation is done off-line on the pre-operative CT data.

With the intra-operative navigation component we bring registration and visualization into the operating room. The pre-operative CT data can be registered with a particular X-ray image, wherein the stent is visible. Afterwards, the CT volume can be visualized in such a way that it contains both the actual and desired position of the stent. For the first time, this enables the surgeons to utilize three-dimensional information for the endovascular stenting procedure. The segmentation algorithms were already tested on real patient data. The navigation system has only been tested on phantom data until now. Nevertheless, the overall system is ready to be tested during an intervention.

The overall system provides the surgeon with a powerful tool to automate the segmentation of the aorta and aneurysm. It also enables easy and more accurate stent navigation towards the aneurysm. Additionally, this solution results in a significant reduction of radiation exposure and contrast agent injection for the patient.

References

- [1] K. Orend, T. Kotsis, R. Scharrer-Palmer, X. Kapfer, F. Liewald, J. Gorich, and L. Sunder-Plassmann, Endovascular Repair of Aortic Rupture due to Trauma and Aneurysm, *European Journal of Vascular and Endovascular Surgery*, 23(1), Januray 2002, pp. 61–67.
- [2] F. Criado, N. Clark, and M. Barnatan, Stent graft repair in the aortic arch and descending thoracic aorta: a 4-year experience, *Journal of Vascular Surgery*, 36(6), December 2002, pp. 1121–1128.
- [3] Yuri Boykov and Marie-Pierre, Jolly Interactive Organ Segmentation using Graph Cuts. Proc.of MICCAI 2000, LNC 1935, pp.276-286
- [4] Richard Hartley and Andrew Zisserman, *Multiple View Geometry in Computer Vision*, Second Edition, 2004