

This is an Open Access article licensed under the terms of the Creative Commons Attribution-NonCommercial-NoDerivs 3.0 License (www.karger.com/OA-license), applicable to the online version of the article only. Distribution for non-commercial purposes only.

First Experiences with Navigated Radio-Guided Surgery Using Freehand SPECT

A. Rieger^a J. Saeckl^a B. Belloni^b R. Hein^b A. Okur^c
K. Scheidhauer^c T. Wendler^d J. Traub^d H. Friess^a
M.E. Martignoni^a

Departments of ^aSurgery, ^bDermatology, and ^cNuclear Medicine, Technische Universität München, and ^dSurgicEye GmbH, Munich, Germany

Key Words

Sentinel lymph node biopsy · Freehand SPECT · Melanoma

Abstract

Background: Sentinel lymph node biopsy (SLNB) in melanoma using one-dimensional gamma probes is a standard of care worldwide. Reports on the performance are claimed by most groups to successfully detect the SLNs during the surgical procedure in almost 100% of the patients. In clinical practice, however, several issues remain which are usually not addressed: the difficulty of intraoperative detection of deeply located nodes, SLN detection in obese patients or in the groin and the impossibility to make a scan of the entire wound after SLN resection to avoid false negative testing for eventually remaining SLNs.

Materials and Methods: The concept behind freehand SPECT is to combine a gamma probe as used for conventional radio-guided surgery with a tracking system as used in neurosurgical navigation. From this combination and a proper algorithm framework the 3D reconstruction of radioactivity distributions and displaying these intraoperatively is possible.

Conclusion: In summary, the feasibility of freehand SPECT could be shown and provides an image-guided SLNB and a truly minimally invasive and optimized surgical procedure.

Introduction

Sentinel lymph node biopsy (SLNB) in melanoma using one-dimensional gamma probes is a standard of care worldwide [1]. In reports on its performance, most groups claim that SLNB successfully detects the SLNs during the surgical procedure in almost 100% of the patients. In clinical practice, however, several issues remain, which are

usually not addressed: the difficulty of intraoperative detection of deeply located nodes, and SLN detection in obese patients or in the groin [2]. Moreover, the fact that often a ‘dissection’ is performed rather than a ‘biopsy’, involving far more nodes than needed, and the impossibility to make a scan of the entire wound after SLN resection probably results in a higher false-negative rate [3]. These aspects could be addressed with proper intraoperative imaging and navigation. We report on our first experience using freehand SPECT for navigated SLNB and comment on how this technology may help making SLNB less invasive and a highly successful procedure also in more complicated clinical scenarios.

Materials and Methods

Freehand SPECT imaging is a novel imaging modality enabling 3D nuclear imaging and navigation in the operating room. The concept behind freehand SPECT is to combine a gamma probe as used for conventional radio-guided surgery with a tracking system as used in neurosurgical navigation. From this combination and a proper algorithm framework, the 3D reconstruction of radioactivity distributions is possible [4]. For the image acquisition, freehand SPECT uses the movement of the gamma probe that the surgeon performs when looking for the structure of interest. This movement is ‘tracked’ by the tracking system and synchronized with the readings of the probe in counts per second. These data are then passed on to the reconstruction algorithm which generates a 3D image out of it. The resulting 3D data allow the calculation and display of the depth of the target structures. Despite the fact that freehand SPECT produces snapshot images (~2-min acquisition time), its 3D nature and navigation extension allow precise localization and instrument guidance at any time of the surgical procedure.

A patient with initial diagnosis of malignant melanoma undergoing SLNB was scanned intraoperatively using a freehand SPECT system (declipseSPECT; SurgicEye GmbH, Munich, Germany). Preoperative labeling of the SLN and consecutive planar scintigraphy was done the day before surgery using Tc99m-nanocoll (88 MBq/2.4 mCi, 4 peritumoral deposits of 0.2 ml).

The surgical procedure was performed approximately 18 h later. The entire protocol consisted of 6 steps: (1) anesthesia, (2) pre-incision freehand SPECT acquisition and visualization of freehand SPECT data, (3) skin incision and SLN biopsy, (4) post-resection freehand SPECT acquisition and visualization, (5) biopsy of additionally detected SLNs using the information derived from freehand SPECT, and (6) suture. Steps (4) and (5) were repeated as long as SLNs were detected in post-resection scans.

Imaging exclusively included the area in which preoperative scintigraphy indicated SLNs. The protocol for the conventional scintigraphy consisted of dynamic frames of 2 min each in anteroposterior and lateral direction (fig. 1a–c). In the pre-incision images, freehand SPECT managed to localize 3 SLNs also visible at preoperative planar scintigraphy 18 h earlier. Image-guided incision was performed using an overlay of radioactivity distribution on a live video of the patient (fig. 2a). After resection of the SLNs, the wound was scanned with the gamma probe alone in order to screen for remaining radioactivity. Subsequently, a freehand SPECT image was acquired in order to visualize remaining activity within the region. Freehand SPECT allowed the detection of remaining SLNs in two iterations (fig. 2b, c).

Discussion

SLNB in melanoma has turned into a well-accepted standardized procedure with clear guidelines. Although the intraoperative detection rate is almost 100% and the false-negative rate is commonly below 5% [5], some groups report false-negative rates of up to 15–20% [3] and difficulties detecting SLNs in patients with comorbidity (in particular in obese patients) and in procedures in the groin [2].

In order to improve these issues, intraoperative 2D gamma imaging systems have been proposed for SLNB [6]. The idea is to provide a more intuitive imaging of the SLNs within the operating room, minimizing false interpretations and making the procedure simpler for less experienced surgeons. Such systems fail, however, to provide depth information and still lack an intuitive visualization in relation to the anatomy. Freehand SPECT [7] may prove to be a more intuitive and powerful tool for improvement of SLNB. Firstly, the system has a potential to reduce the invasiveness of SLNB due to the newly available depth information and overlay on a video image of the operating site. Image-guided incision may be particularly interesting in the region of the groin and may reduce the duration of the surgical procedure. Secondly, as in the case of mini gamma cameras, the freehand SPECT system may show a higher sensitivity than a gamma probe alone. This is potentially useful in patients with a higher body weight. Thirdly, interventional imaging allows confirming complete resection of all SLNs and may play a role for proper documentation and quality assessment. Finally, the intuitive visualization of data may allow the SLNB procedure to be performed with higher quality by less experienced physicians.

In summary, these initial results show the potential of freehand SPECT enabling image-guided SLNB and a truly minimally invasive and optimized surgical procedure.

Acknowledgements

This research was partly funded/supported by the Graduate School of Information Science in Health (GSISH), the TUM Graduate School and DFG's SFB824.

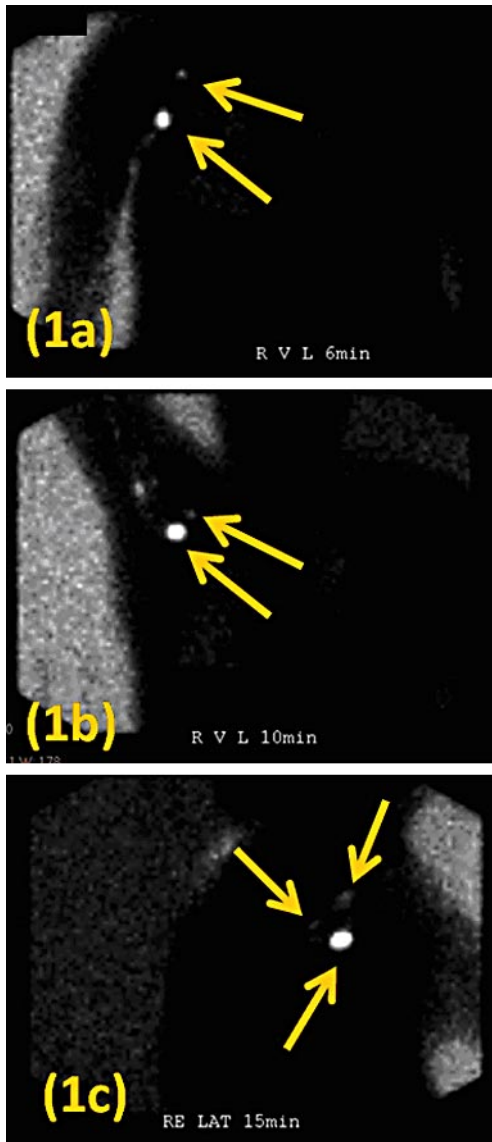


Fig. 1. Preoperative dynamic scintigraphy showing 3 axillary nodes: **a** Anteroposterior image 6 min after injection with arm in lower position, **b** anteroposterior image 10 min after injection with arm in upper position, **c** lateral image 15 min after injection.

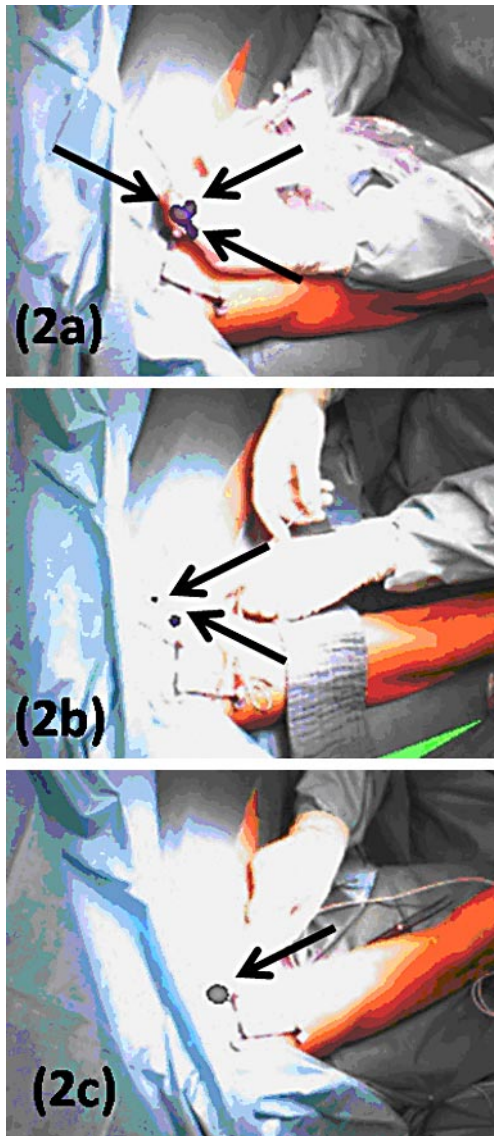


Fig. 2. Intraoperative freehand SPECT image overlaid over video of patient showing the same topology as preoperative scintigraphy before incision (**a**) and then the successive biopsy of the SLNs (**b, c**).

References

- 1 Coit DG, Andtbacka R, Bichakjian CK, Carson WE, Dilawari RA, Dimaio D, Guild V, Halpern AC, Hodi FS, Kashani-Sabet M, Kelley MC, Lange JR, Lind A, Martin L, Martini MC, Pruitt SK, Ross MI, Wetter SM, Tanabe KK, Thompson JA, Trisal V, Urist MM, Weber J, Wong MK: NCCN Clinical Practice Guidelines in Oncology: Melanoma. Fort Washington, National Comprehensive Cancer Network, 2010.
- 2 Ling A, Dawkins R, Bailey M, Leung M, Cleland H, Serpell J, Kelly J: Short-term morbidity associated with sentinel lymph node biopsy in cutaneous malignant melanoma. *Australas J Dermatol* 2010;51:13–17.
- 3 Testori A, De Salvo GL, Montesco MC, Trifirò G, Mocellin S, Landi G, Macripò G, Carcoforo P, Ricotti G, Giudice G, Picciotto F, Donner D, Di Filippo F, Soteldo J, Casara D, Schiavon M, Vecchiato A, Pasquali S, Baldini F, Mazzarol G, Rossi CR; Italian Melanoma Intergroup: Clinical considerations on sentinel node biopsy in melanoma from an Italian multicentric study on 1,313 patients (SOLISM-IMI). *Ann Surg Oncol* 2009;16:2018–2027.
- 4 Wendler T, Hartl A, Lasser T, Traub J, Daghigian F, Ziegler SI, Navab N: Towards intra-operative 3D nuclear imaging: reconstruction of 3D radioactive distributions using tracked gamma probes. *Med Image Comput Comput Assist Interv* 2007;10(Pt 2):909–917.
- 5 American Society of Plastic Surgeons: Evidence-Based Clinical Practice Guideline: Treatment of Cutaneous Melanoma. Arlington Heights, ASPS, 2007.
- 6 Pina Hernández JD, Priego P, Mena A, Cabañas J, Arana J, Cabañas L, Molina Villar JM, Fresneda Moreno V: Melanoma de cuero cabelludo y técnica de ganglio centinela con gammacámara portátil. *Cir Esp* 2008;84(Espec Congr 2):1–283 XXVII Congreso Nacional de Cirugía.
- 7 Wendler T, Herrmann K, Schnelzer A, Lasser T, Traub J, Kutter O, Ehlerding A, Scheidhauer K, Schuster T, Kiechle M, Schwaiger M, Navab N, Ziegler SI, Buck AK: First demonstration of 3-D lymphatic mapping in breast cancer using freehand SPECT. *Eur J Nucl Med Mol Imaging* 2010;37:1452–1461.