

An Open Source Multimodal Image-guided Prostate Biopsy Framework

Amit Shah¹, Oliver Zettinig¹, Tobias Maurer², Cristina Precup¹,
Christian Schulte zu Berge¹, Jakob Weiss¹, Benjamin Frisch¹, and
Nassir Navab¹

¹ Computer Aided Medical Procedures, Technische Universität München, Germany

² Poliklinik und Klinik für Urologie, Klinikum Rechts der Isar, Technische Universität München, Germany

Abstract. Although various modalities are used in prostate cancer imaging, transrectal ultrasound (TRUS) guided biopsy remains the gold standard for diagnosis. However, TRUS suffers from low sensitivity, leading to an elevated rate of false negative results. Magnetic Resonance Imaging (MRI) on the other hand provides currently the most accurate image-based evaluation of the prostate. Thus, TRUS/MRI fusion image-guided biopsy has evolved to be the method of choice to circumvent the limitations of TRUS-only biopsy. Most commercial frameworks that offer such a solution rely on rigid TRUS/MRI fusion and rarely use additional information from other modalities such as Positron Emission Tomography (PET). Other frameworks require long interaction times and are complex to integrate with the clinical workflow. Available solutions are not fully able to meet the clinical requirements of speed and high precision at low cost simultaneously. We introduce an open source fusion biopsy framework that is low cost, simple to use and has minimal overhead in clinical workflow. Hence, it is ideal as a research platform for the implementation and rapid bench to bedside translation of new image registration and visualization approaches. We present the current status of the framework that uses pre-interventional PET and MRI rigidly registered with 3D TRUS for prostate biopsy guidance and discuss results from first clinical cases.

Keywords: Prostate Cancer, Multimodal Image-guided Biopsy, PET, MRI, TRUS, Open Source Software

1 Introduction

Prostate cancer is one of the most common cancers worldwide [1]. However, survival rates are high if it is diagnosed early and treated on time. The gold standard to confirm prostate cancer is transrectal ultrasound (TRUS) guided systematic 10 to 12 core biopsy. Although TRUS provides real-time anatomical guidance, its sensitivity for prostate cancer is rather low. Hence, TRUS guided systematic biopsies may miss important cancer sites [12]. On the other hand, multi-parametric MRI and PET have higher cancer detection rate as reported

in the studies presented in the review paper by Turkbey et al. [12]. Further studies [3, 6, 10] have shown that TRUS/MRI fusion image-guided targeted biopsy might detect significantly more malignant lesions compared to using TRUS alone.

Many urology clinics have access to advanced imaging modalities such as CT, MRI or nuclear medicine and an increasing number of urologists performs cognitive fusion of these multimodal images while performing TRUS guided biopsy. However, cognitive fusion is prone to human error and does not improve the results significantly as presented by Delongchamps et al. [3]. Hence, automatic fusion of pre-interventional imaging, especially of MRI and PET with TRUS, is highly desired.

Literature Review One challenge lies in combining pre-interventional multimodal images with interventional TRUS automatically, with acceptable accuracy and without exceeding the permissible time limits of the clinical workflow. Efforts towards TRUS/MRI registration are summarized by Sperling et al. [10]. While classical approaches mostly rely on either surface based or extracted fiducial driven algorithms, more recent approaches attempt deformable registration based on prostate surface models using spline basis functions [7] or on probabilistic and statistical shape models [9]. These algorithms rely on the manual segmentation of prostate surfaces which requires an extended interaction of the physician, which makes it difficult to integrate into the clinical routine.

A further challenge is the development of a biopsy system that uses such fusion images for guidance. Commercial solutions come each with their drawbacks, reducing their acceptance in urological routine. Most systems use 2D TRUS probes and track their position to compound a 3D TRUS image. PercuNav (Philips, NL) and Hi-RVS (Hitachi, JP) both use electromagnetic tracking, subject to disturbances of the electromagnetic field and ensuing low tracking accuracy. Artemis (Eigen, US) requires a mechanical arm to record the position of the US probe and does surface based TRUS/MRI elastic registration. The BioJET (GeoScan, USA) and BiopSee (Medcom, DE) systems both mount the US probe on a stepper to acquire information about the position of the US probe. To our knowledge, only the Koelis system (Uronav, France) avoids the challenges of a tracking system by using a 3D TRUS probe. It uses elastic registration algorithms but requires TRUS/TRUS registration as an intermediate step for TRUS/MRI registration.

Until recently, PET/TRUS fusion for prostate biopsy has generated only moderate interest mainly due to the low specificity of currently available tracers like ^{11}C -acetate, ^{11}C -choline and ^{18}F -FDG [12]. However, with the introduction of ^{68}Ga labelled ligands of Prostate Specific Membrane Antigen (PSMA), PET/TRUS fusion might gain increasing attention [4].

Proposed Solution In this work, we propose a solution that leverages the use of open source software to develop a multimodal image-guided system for transrectal prostate biopsy that combines pre-interventional PET-MRI with interventional 3D TRUS. This low cost approach aims at providing a research platform for the implementation and rapid translation into clinical use of new image registration and visualisation approaches. We use the PLUS framework [5]

for ultrasound probe calibration, tracked image acquisition and volume reconstruction. PLUS requires further packages such as ITK for image processing [14], VTK for visualization [8] and OpenIGTLink [11] for communication with other systems. Our application is developed using CAMPVis [2], an open source visualization framework from our group, that offers image registration and real-time slice rendering based on tracking information.

The software components and the targeted biopsy system are explained in section 2. The outcomes of first clinical cases using rigid landmark-based registration are presented in section 3. The conclusion and future work are outlined in section 4.

2 Method

2.1 System Setup

Our system, illustrated in Fig. 1, is lightweight in terms of workflow and resources. It consists of a conventional ultrasound system, optical tracking and a workstation. The ultrasound system is a Hitachi AVIUS with a front fire trans-rectal probe that provides 2D ultrasound images. The ultrasound probe is tracked by an NDI Polaris[®] optical tracking system. Since we do not have direct access to RF data from the ultrasound machine, we use a frame grabber to acquire high resolution 1280x1024 digital images. The workstation has 2 Intel Xeon[®] processors running at 2.13 GHz with 32GB RAM and a NVIDIA GeForce[®] 8800 GTS 512 Graphics card. The 3D TRUS image acquisition and biopsy guidance are based on PLUS and CAMPVis respectively, both are open source software frameworks for medical applications.

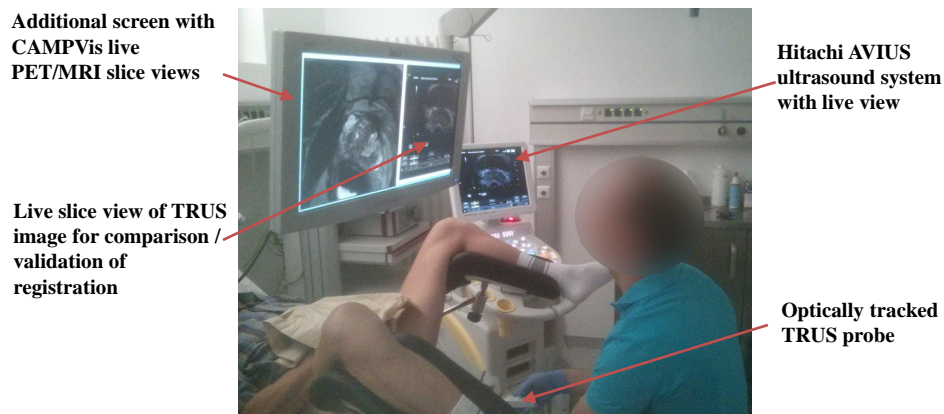

Fig. 1. Urologist performing prostate biopsy using multimodal image guidance.

2.2 Clinical Protocol

The 3D TRUS acquisition and PET-MRI-TRUS registration procedure were easily integrated into the existing clinical workflow without much overhead in time or effort. Fig. 2 shows the steps in the multimodal image-guided prostate biopsy. The system has already been used for biopsies of two patients, after obtaining their informed consent.

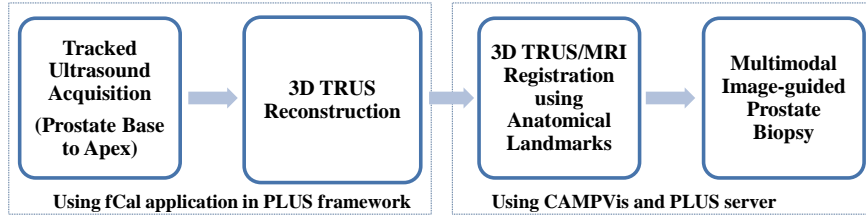


Fig. 2. Overview of the clinical procedure for multimodal image-guided prostate biopsy.

3D TRUS Acquisition using PLUS The first step in the fusion image-guided biopsy procedure is to acquire a 3D TRUS volume. This requires the spatial calibration of the ultrasound probe, a tracked ultrasound acquisition and reconstruction of the 3D volume from 2D ultrasound slices. All these steps are performed as per the methods given in Lasso et al. in [5].

Temporal and Spatial Calibration An optical target, tracked by the optical tracking system (transformation ${}^{probe}T_{world}$), is mounted on the shaft of the front fire TRUS probe, opposite of the biopsy needle guide. The ultrasound images are acquired in a high resolution digital format at 30 fps using a frame grabber card. This maintains compatibility to other ultrasound systems. Temporal calibration is done to account for any time lag between the tracking and the video frame. The spatial transformation ${}^{frame}T_{probe}$ between the image frame origin and the optical target is found using fCal application and a 3N-wire phantom provided in PLUS. It should be noted that this calibration procedure has to be performed only once as long as the target is fixed to the probe and the ultrasound image parameters, such as depth and focus, remain constant.

Tracked Ultrasound and Compounding Another optical target, which acts as a reference (transformation ${}^{ref}T_{world}$), is attached to the biopsy chair where the patient is positioned in the lithotomy position. Using fCal, tracked ultrasound frames are continuously recorded while the urologist manually moves the probe from the prostate base to the apex. Applying a forward warping technique, the tracked frames are then compounded into a 3D TRUS volume. Hereby, the transformation ${}^{ref}T_{chair}$ between the reference target and the standard axes of the chair allows to align the 3D TRUS axes according to the DICOM standard, in order to reposition the volumes for subsequent registration. Fig. 3 shows all

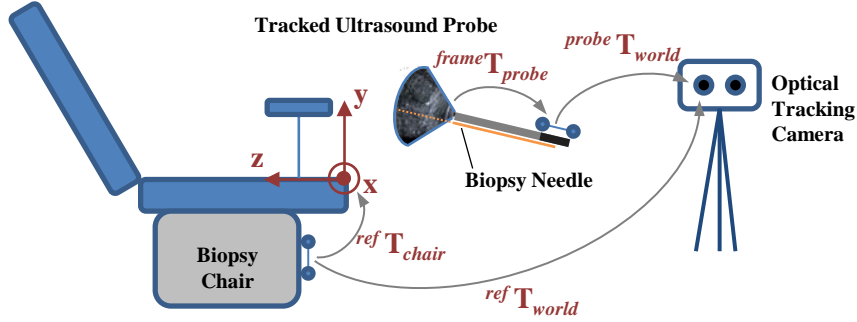


Fig. 3. Schematic setup, illustrating coordinate systems and transformations.

transformations mentioned in Eq. 1:

$$frameT_{3DTRUS} = {}^{ref}T_{chair} \cdot ({}^{ref}T_{world})^{-1} \cdot {}^{probe}T_{world} \cdot {}^{frame}T_{probe} \quad (1)$$

Landmark-based Image Registration in CAMPVis In order to align the MRI and acquired 3D TRUS volumes, a landmark-based image registration is performed. To that end, axial, coronal or sagittal slices of both images are presented in CAMPVis next to each other, allowing the urologist to select four corresponding anatomical landmarks by mouse clicks. Employing the Umeyama method [13], the rigid transformation ${}^{MRI}T_{3DTRUS}$ is solved and a fused image is presented to the physician. As PET and MRI volumes are acquired with a Siemens integrated wholebody PET-MRI scanner, they are intrinsically registered to each other, facilitating a transfer of lesions from PET to MRI images as shown in Fig. 4. As a result, the multimodal image registration is quickly achieved and can be performed in clinical routine without interrupting the procedure, during the preparation of local anesthesia.

Tracking & Navigation for Biopsy Guidance The final step of the procedure is a targeted biopsy under multimodal image guidance. Apart from the 2D live ultrasound image shown on the screen of the ultrasound scanner, our framework provides the urologist in real time with corresponding slice views of one or more pre-operative images such as PET or MRI (cf. Fig. 1). In CAMPVis, the correct slicing planes are determined by the x- and y-axes of the following coordinate system:

$${}^{frame}T_{MRI} = ({}^{MRI}T_{3DTRUS})^{-1} \cdot {}^{frame}T_{3DTRUS} \quad (2)$$

For the computation of ${}^{frame}T_{3DTRUS}$, only the current tracked positions of the ultrasound probe and the reference target need to be updated, which is achieved by forwarding tracking information from the PLUS server over the OpenIGTLink protocol. For navigation, a virtual biopsy guide that indicates an approximate needle insertion path is provided by the ultrasound machine and shown on the live ultrasound image. The urologist maneuvers the probe such that the virtual biopsy guide aligns with the target and biopsies are taken.

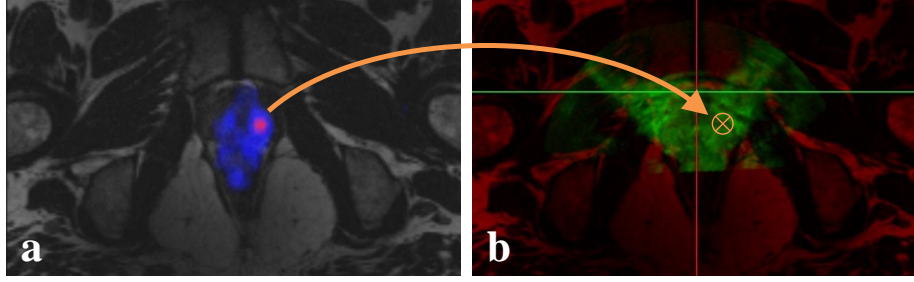


Fig. 4. Transfer of biopsy targets from PET to 3D TRUS via MRI for patient case 1. **a)** PET/MRI with targets in pink, **b)** 3D TRUS (green) registered to MRI image (red) after landmark-based registration.

3 Results

The first prototype of this platform was assessed in two patients, after they gave their informed consent, by an experienced urologist as per the workflow in Fig. 2. These patients had a clinical suspicion of prostate cancer but previously negative biopsy results. Hence, the patients underwent PET-MRI examination before the biopsy procedure. Fig. 1 shows the system setup in our urology clinic during the fusion biopsy procedure.

System Performance The time taken for the 3D TRUS acquisition and TRUS/MRI registration was less than 10 minutes in both clinical cases. The tracked ultrasound acquisition is done during a routine US prostate examination that precedes every biopsy. The registration is performed in less than 5 minutes while the patient is waiting for the local anaesthesia to take effect. Thus, there is not much overhead in time as compared to conventional TRUS-guided systematic prostate biopsy. Fig. 4 (a) shows the PET-MRI image of patient number 1 for the identification of targets for biopsy. Fig. 4 (b) shows the TRUS/MRI fusion image after anatomical landmark-based registration for the same patient.

Clinical Cases The clinical cases of two patients are summarized in Tab. 1. In both cases, the MRI was equivocal and the PET image revealed suspicious regions.

Table 1. Overview of clinical data and results using proposed targeted biopsy system.

Case	PSA Value (ng/ml)	Targeted Biopsy	Histology Results
1	5.4	2	prostate carcinoma left apical
2	7.5	2	no malignancy

Case 1 was a 45 year-old patient, *status post* a previous prostate biopsy one year ago with no malignancies found. With a rising PSA value of currently 5.4 ng/ml, the ^{68}Ga PSMA PET-MRI showed a highly suspicious area in the left

apical central zone. For the systematic biopsy (10 cores), histology examination identified prostate carcinoma with a Gleason score of 6 in the left apical and the left central region of the prostate. The two targeted biopsy samples were also tested positive in histology, confirming a prostate carcinoma in the left apical site. Therefore, our system was able to identify, map and target the suspicious region for prostate cancer diagnosis.

Case 2 was a 58 year-old patient. Similarly to case 1, no malignancies had been identified in a previous prostate biopsy. Due to a rising PSA value of currently 7.5 ng/ml, the patient underwent ^{68}Ga PSMA PET-MRI, which showed only a slight expression of PSMA in the median peripheral zone on both sides and a moderate suspicion of prostate cancer. Histology results were negative for both the 10-core systematic biopsy and the 2-core targeted biopsy.

4 Conclusion

We presented a fusion image-guided system for targeted prostate biopsy based on open source software. We presented preliminary clinical results in two patients. We used PET-MRI images registered with 3D TRUS to identify, map and guide the biopsy. The time and resource overhead for the entire procedure compared to the conventional biopsy routine was minimal.

This open source software solution has many advantages that makes it ideal as a research platform. It is extremely useful for translational clinical research and can serve as a test bench to evaluate the medical impact of new developments. It further offers flexibility to modify or extend the software applications and community support for the development. The code sharing helps for rapid development and prevents duplicating research efforts. The overall system cost is significantly reduced compared to commercially available systems. Translating this prototype into a fully clinically acceptable solution will require further efforts.

We will extend the framework with advanced registration and visualisation algorithms that may further simplify the procedure and increase the precision in targeted biopsy.

Acknowledgments This work is partially supported by the EU 7th Framework Program projects Marie Curie Early Initial Training Network Fellowship (PITN-GA-2011-289355-PicoSEC-MCNet), EndoTOFPET-US (GA-FP7/2007-2013-256984), ACTIVE (FP7/ICT-2009-6-270460), and SoftwareCampus program of the German Federal Ministry of Education and Research (BMBF, Förderkennzeichen 01IS12057).

References

1. Worldwide cancer key facts 2014, cancer research uk, http://publications.cancerresearchuk.org/downloads/Product/CS_KF_WORLDWIDE.pdf

2. Schulte zu Berge, C., Grunau, A., Mahmud, H., Navab, N.: CAMPVis – A Game Engine-inspired Research Framework for Medical Imaging and Visualization. Tech. rep., Technische Universität München (2014), <http://campar.in.tum.de/Main/CAMPVis>
3. Delongchamps, N.B., Peyromaure, M., Schull, A., Beuvon, F., Bouazza, N., Flam, T., Zerbib, M., Muradyan, N., Legman, P., Cornud, F.: Prebiopsy magnetic resonance imaging and prostate cancer detection: comparison of random and targeted biopsies. *The Journal of urology* 189(2), 493–499 (2013)
4. Eiber, M., Maurer, T., Beer, A., Souvatzoglou, M., Holzapfel, K., Ruffani, A., Wester, H., Schwaiger, M.: Detection rate for a novel 68ga-psma pet-ligand in patients with biochemical recurrence of prostate cancer using pet/ct and pet/mr imaging. In: *Society of Nuclear Medicine Annual Meeting Abstracts*. vol. 55, p. 13. Soc Nuclear Med (2014)
5. Lasso, A., Heffter, T., Rankin, A., Pinter, C., Ungi, T., Fichtinger, G.: Plus: open-source toolkit for ultrasound-guided intervention systems. *Transactions in Biomedical Engineering*, IEEE (2014)
6. Marks, L., Young, S., Natarajan, S.: Mri-ultrasound fusion for guidance of targeted prostate biopsy. *Current opinion in urology* 23(1), 43 (2013)
7. Mitra, J., Kato, Z., Martí, R., Oliver, A., Lladó, X., Sidibé, D., Ghose, S., Vilanova, J.C., Comet, J., Meriaudeau, F.: A spline-based non-linear diffeomorphism for multimodal prostate registration. *Medical Image Analysis* 16(6), 1259–1279 (2012)
8. Schroeder, W.J.: *The visualization toolkit user s guide: updated for version 4.0*. Kitware (1998)
9. Sparks, R., Bloch, B.N., Feleppa, E., Barratt, D., Madabhushi, A.: Fully automated prostate magnetic resonance imaging and transrectal ultrasound fusion via a probabilistic registration metric. In: *SPIE Medical Imaging*. pp. 86710A–86710A. International Society for Optics and Photonics (2013)
10. Sperling, D.: Mri-ultrasound fusion imaging. In: *Image Guided Prostate Cancer Treatments*, pp. 115–123. Springer (2014)
11. Tokuda, J., Fischer, G.S., Papademetris, X., Yaniv, Z., Ibanez, L., Cheng, P., Liu, H., Blevins, J., Arata, J., Golby, A.J., et al.: Openiglink: an open network protocol for image-guided therapy environment. *The International Journal of Medical Robotics and Computer Assisted Surgery* 5(4), 423–434 (2009)
12. Turkbey, B., Pinto, P.A., Choyke, P.L.: Imaging techniques for prostate cancer: implications for focal therapy. *Nature Reviews Urology* 6(4), 191–203 (2009)
13. Umeyama, S.: Least-squares estimation of transformation parameters between two point patterns. *IEEE Transactions on pattern analysis and machine intelligence* 13(4), 376–380 (1991)
14. Yoo, T.S., Ackerman, M.J., Lorensen, W.E., Schroeder, W., Chalana, V., Aylward, S., Metaxas, D., Whitaker, R.: Engineering and algorithm design for an image processing api: A technical report on itk-the insight toolkit. *Studies in health technology and informatics* pp. 586–592 (2002)