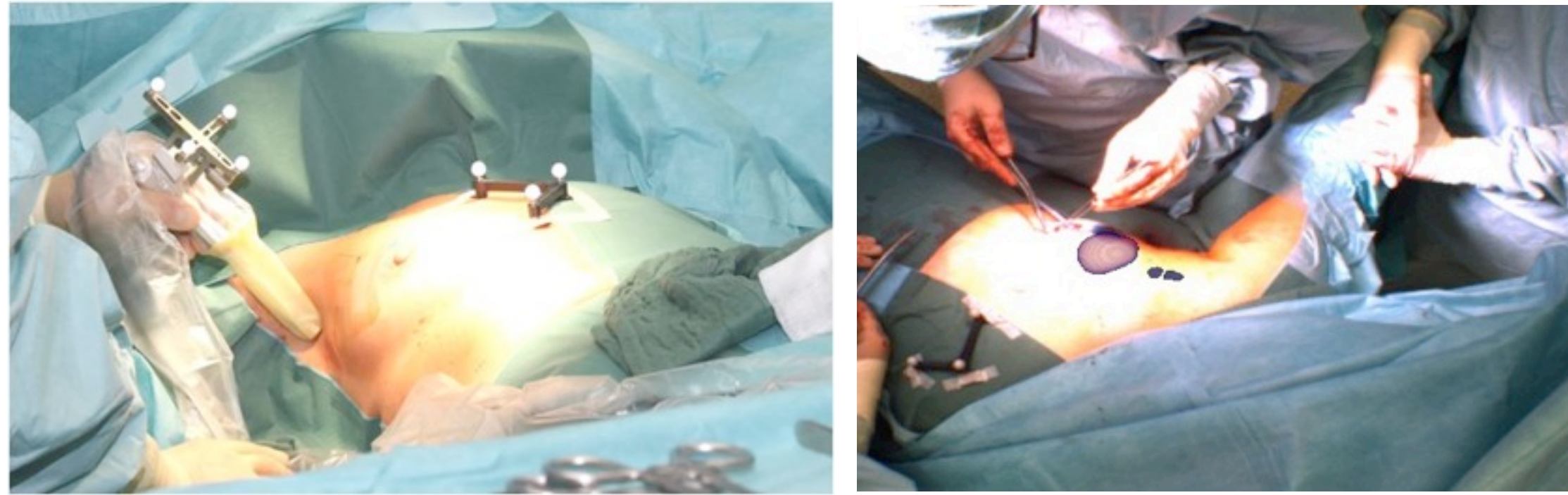


1. PURPOSE

Intraoperative hybrid imaging provides additional diagnostic information in combination with improved surgical navigation.

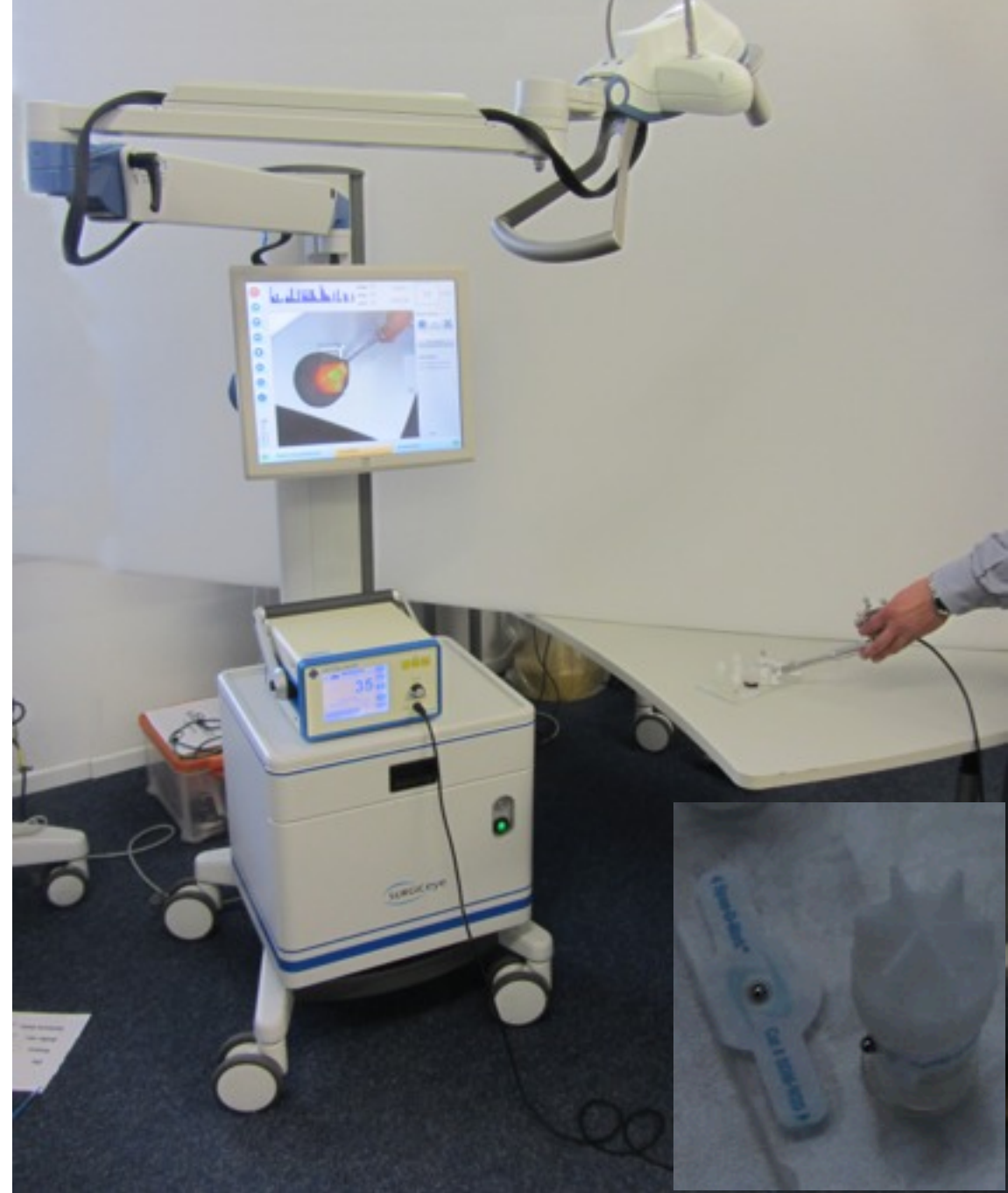

Tracked imaging with handheld gamma probes (e.g. with retro-reflective infrared markers on patient and gamma probe and stereo video cameras - as implemented in freehand SPECT - or fhSPECT) can provide excellent 3D imaging of radioactively marked tumor as well as lymph nodes in the surgical suite and subsequent navigation to remove the tissue and verify the surgical result (1)(2) - see images (augmented reality mode) below.



fhSPECT however misses information about surrounding tissues and organs that do not absorb radiopharmaceuticals and are therefore not contributing to the nuclear imaging data. It has been shown that combinations of imaging systems can provide valuable additional information for the surgeon (3). For several applications (4) it could be beneficial to add MRI imaging to the intraoperative nuclear imaging.

3. MATERIALS and METHODS

Image size: 256 x 256
View size: 497 x 497 t1_mprage_sag_1mm - t1_mprage_sag_1mm
WL: 305 WW: 659




A purpose made phantom with 5 small containers was used for the co-referencing images on the handheld SPECT system. The containers were filled with baby oil (PENATEN) and the entire phantom was placed in a water bath. Standard imaging sequences were used on a dedicated Head MRI system (MPRAGE, 1mm slice, TE 3.93, TR 2300 -- 3T, Allegra, Siemens).

Subsequently CT imaging (1.25mm slice thickness, 120kV, 0.59mm spatial resolution, Symbia T6, Siemens) was used as an additional imaging system for the co-registration.

The containers were filled with radioactive Tc-99m (1 MBq each) and the fhSPECT data collection used 1.800 "freehand" measurements in 90s of acquisition time. Registration between CT and fhSPECT images was done using the point based registration according to Umeyama (5) based on the patient retro-reflective spheres (L-shaped structure). Similarly the CT and MR images were registered based on the oil/isotope containers.

The picture left for a setup of the fhSPECT imaging and inserted on the bottom right a detail of the imaging phantom with the radioactive seeds.



2. CONCEPTUAL IDEA / FEASIBILITY

General idea would be to - for example - perform tumor surgery using the imaging information and guidance of an intraoperative SPECT system (in our case DECLIPSE SPECT from SURGICEYE, Munich) and superimpose these images to preoperatively acquired MRI images and subsequently intraoperatively acquired MRI data.

MRI and SPECT data needs to be referenced to each other to use it for intraoperative image guidance.


Referencing Nuclear images to MRI images - by simultaneously or sequentially acquiring the individual data - is possible and has been shown in the past for diagnostic purposes.

Challenges are that intraoperative applications require a certain accuracy, almost real time image updates, and are performed using handheld gamma probes with significantly lower count rates compared to the large detector systems used for diagnostic purposes.

The conceptual idea in the work was to show that the proposed setup (using a handheld 3D SPECT system for intraoperative visualization and navigation in close vicinity to a MRI system) is possible and feasible and will be able to produce results that will be good enough to justify further development efforts. To show feasibility for these type of procedures we developed a custom made phantom useable for MRI and SPECT imaging (see picture above).



4. RESULTS and CONCLUSION



fhSPECT acquired Image CT and fhSPECT fhSPECT registered to MRI

The registration error between MR and fhSPECT (as RMS value) was 3.55mm in X (horizontal), 1.28mm in Y (perpendicular to image plane), and 4.08mm in Z direction (vertical). Maximum deviation was 6.9mm in Z (bottom right container, at the edge of the MRI FOV).

Considering the rudimentary setup and the imaging steps that were necessary to obtain the referencing these results are promising (in all cases less than 10mm deviation). Magnet inhomogeneities, which can contribute to the error, were not taken into consideration.

We are aware that in a real setup in a surgical environment the error margins could get worse, but the results have shown that actual intraoperative applications with combinations of MRI imaging and freehand tracked nuclear imaging (fhSPECT) should be feasible and are possible.

The combination of a nuclear imaging device with a MRI system could provide valuable additional information for intraoperative applications, verifying exact tumor location combined with detailed morphological patient data.

To develop a system that can actually be used in close neighborhood to a MRI system (at or around the 5G line) and that is useable in a surgical setup many several additional aspects need to be improved.

Other ways to more easily and more accurately reference are already works in progress.

MRI compatibility is an obvious challenge, but we have already experimented with nuclear detectors that can are not susceptible to static and dynamic magnetic fields. The main components of the fhSPECT system used can be made MRI safe with some additional R&D effort.

5. References

- (1) O.R. Brouwer, et al. Proceeding of ISNS 2010, Yokohama, Japan, Nov. 2010
- (2) T. Wendler, K. Herrmann, A. Schnelzer, et al.; Eur J Nucl Med Mol Imaging Volume 37, Number 8 / August 2010
- (3) S. Wiesner, P. Dressel, M. Friebe, M. Freesmeyer, N.Navab, T. Wendler, J. Traub; SMIT Congress 2011, Tel Aviv, book of abstracts
- (4) G. Krombach, A. Buecker, J. Pfeffer, C. Hohl, J. Temur, M. Friebe, S. Kinzel, R. Guenther; Abstract and presentation ISMRM 2007, Berlin
- (5) S. Umeyama. IEEE Trans. on Pattern Analysis and Machine Intelligence. 1991, 13(4):376-380.

Correspondence address:

Michael Friebe, PhD, Chair for computer aided medical procedures, TU München + IDTM GmbH

michael@friebe.biz

http://www.idtmt.de