

A Novel Segmentation and Navigation Tool for Endovascular Stenting of Aortic Aneurysms

Marco Feuerstein, Konstantinos Filippatos, Oliver Kutter,
Eva U. Schirmbeck, Robert Bauernschmitt, Nassir Navab

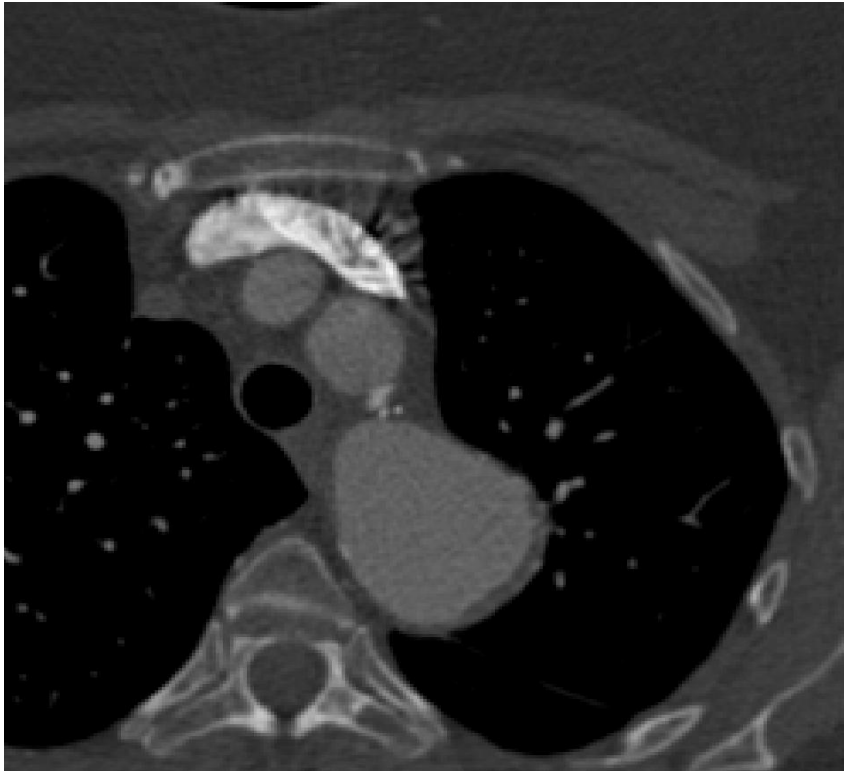
01 July 2006

Chair for Computer Aided Medical Procedures & Augmented Reality

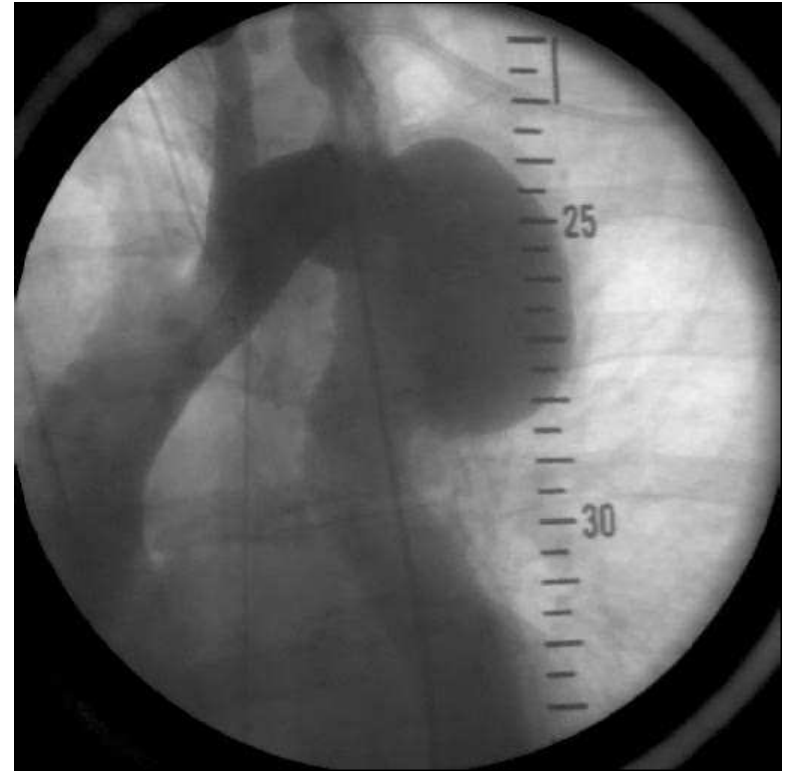
Department of Computer Science | Technische Universität München

Aortic Aneurysm

- Local dilatation of the aorta



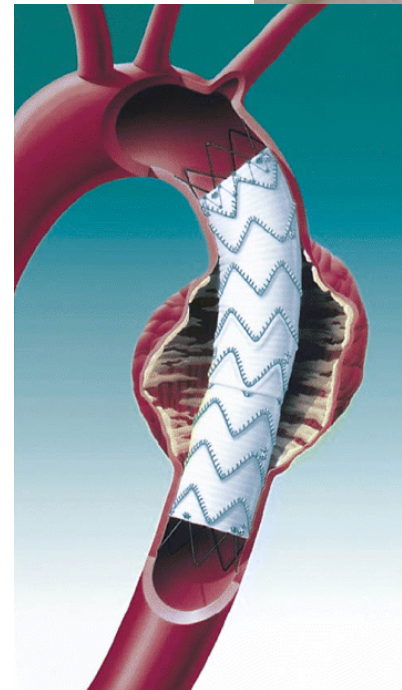
CT



Fluoroscopy

Endovascular Stenting

- Pre-operative CT for detection of the aneurysm and determination of the length and diameter of the stent
- Operative exposure of the femoral artery
- Introduction of a catheter, which the folded stent graft is attached to, until the region of interest (aneurysm) is reached
- Intra-operative angiography (X-rays & contrast injection) for the estimation of the actual stent position and for the implantation
- Unfolding and self-attachment of the stent



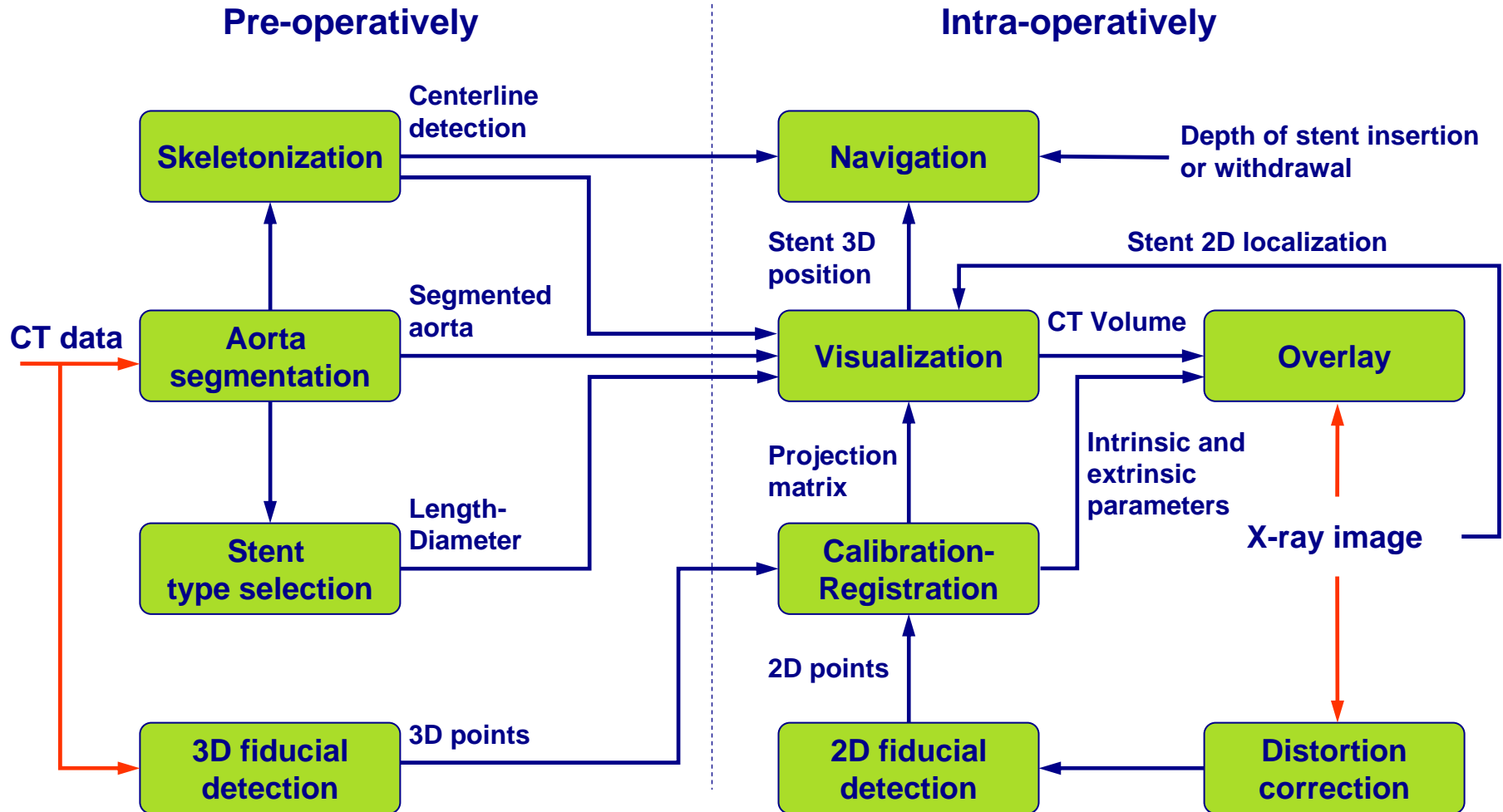
Endovascular Stenting – Problem Statement

- Pre-operative 3D information (incl. planning data) not available in the operating room
- No direct view onto the region of interest
- Frequent use of fluoroscopy (~ 15 – 20 series) → Rather high amount of radiation exposure and contrast agent injection
- *Goals: Reduce radiation exposure, contrast agent injection, make navigation easier and more accurate!*
- **Methods:** Automatic segmentation and easy fiducial-based 2D/3D registration (contrary to DRR-based registration, as e.g. proposed by Imamura, Eiho et al)

[Shigeru Eiho, Hiroshi Imamura, Naozo Sugimoto: **Preoperative and Intraoperative Image Processing for Assisting Endovascular Stent Grafting**, Proceedings of the 12th International Conference on Informatics Research for Development of Knowledge Society Infrastructure (ICKS 2004)]

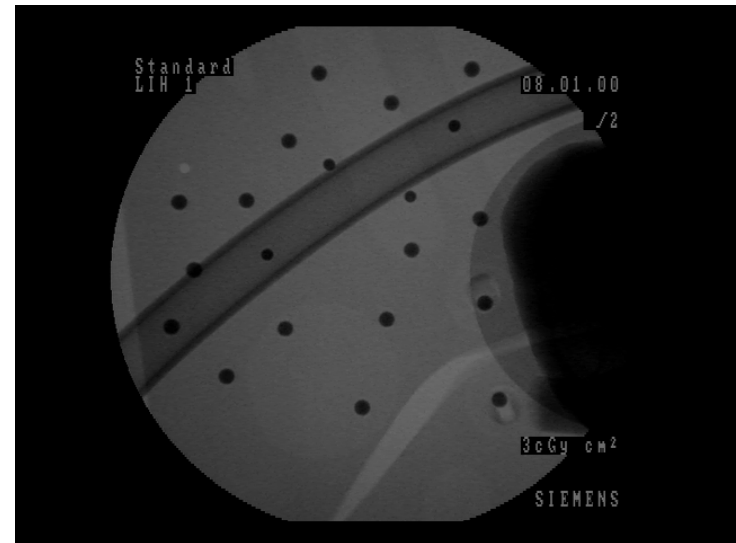

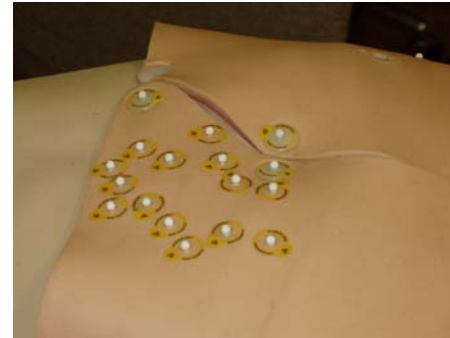
[Hiroshi Imamura, Noriaki Ida, Naozo Sugimoto, Shigeru Eiho, Shin-ichi Urayama, Katsuya Ueno, and Kanji Inoue: **Registration of Preoperative CTA and Intraoperative Fluoroscopic Images for Assisting Aortic Stent Grafting**, MICCAI 2002, Lecture Notes in Computer Science, vol. 2489, pp. 477–484]

Workflow



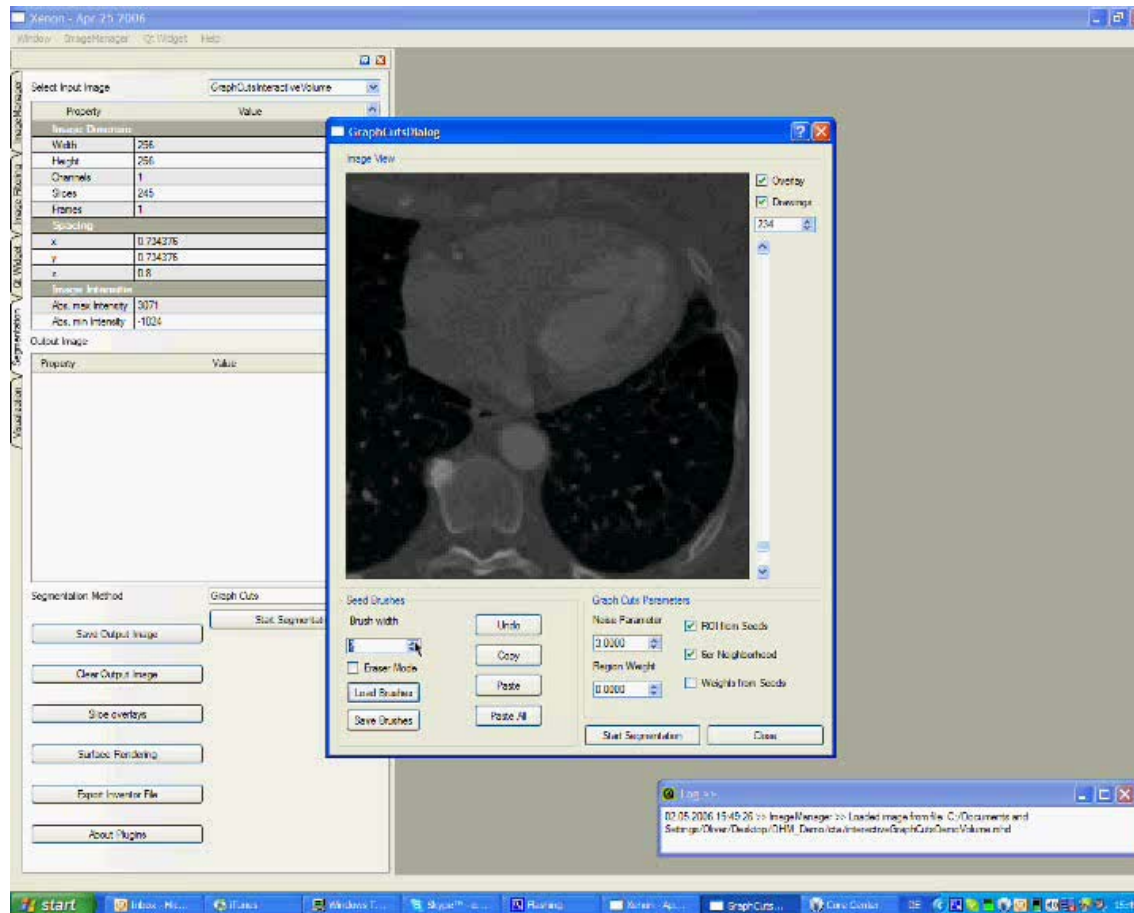
Experimental Setup

- 4 CTAs of real patients for testing of segmentation
- Phantom of the thorax
 - Simulation of the aorta with a tube
 - X-ray visible spherical fiducials, adhered to the skin (top and back) and inside the tube to simulate the intra-operative stent position (ground truth)
 - Imaging data:
 - (pre-operative) CT
 - (intra-operative) X-rays, with not altered fiducial positions



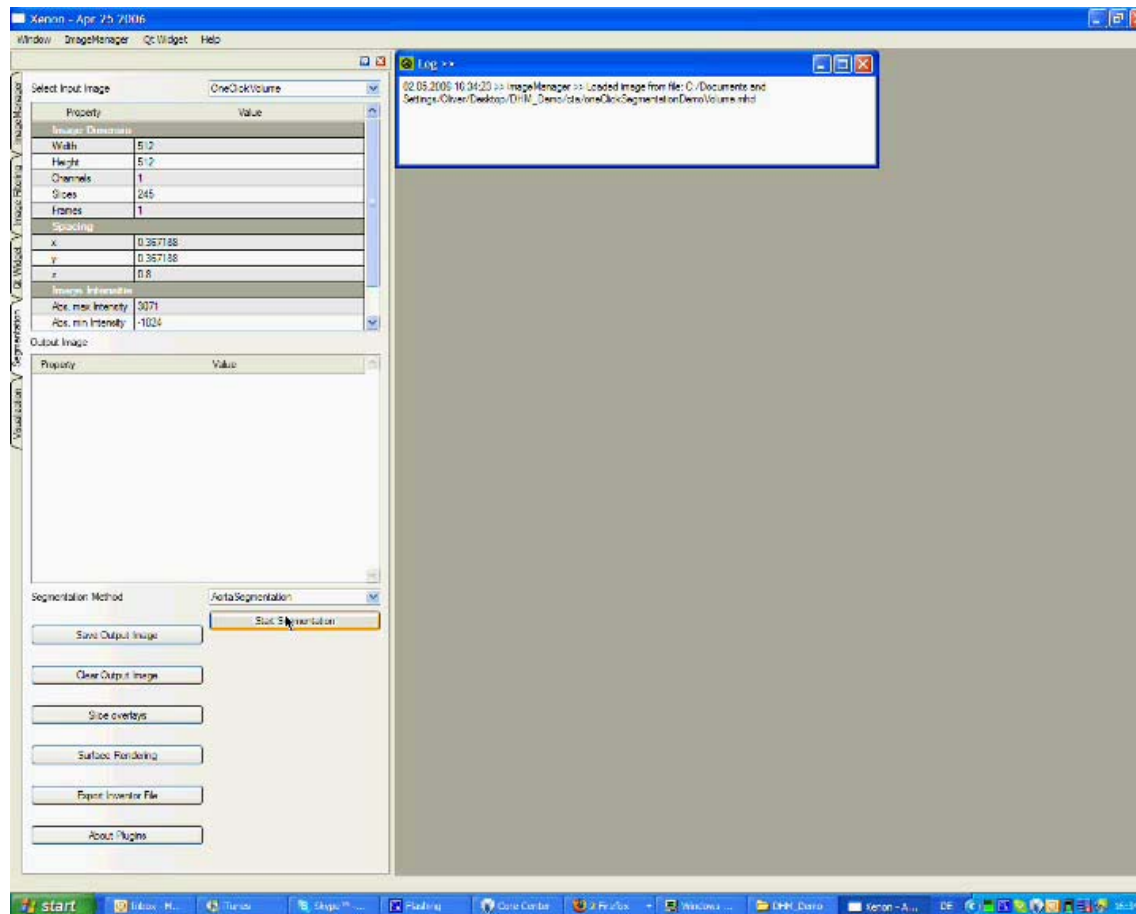
Interactive Aorta Segmentation via Graph Cuts

Video/Demo



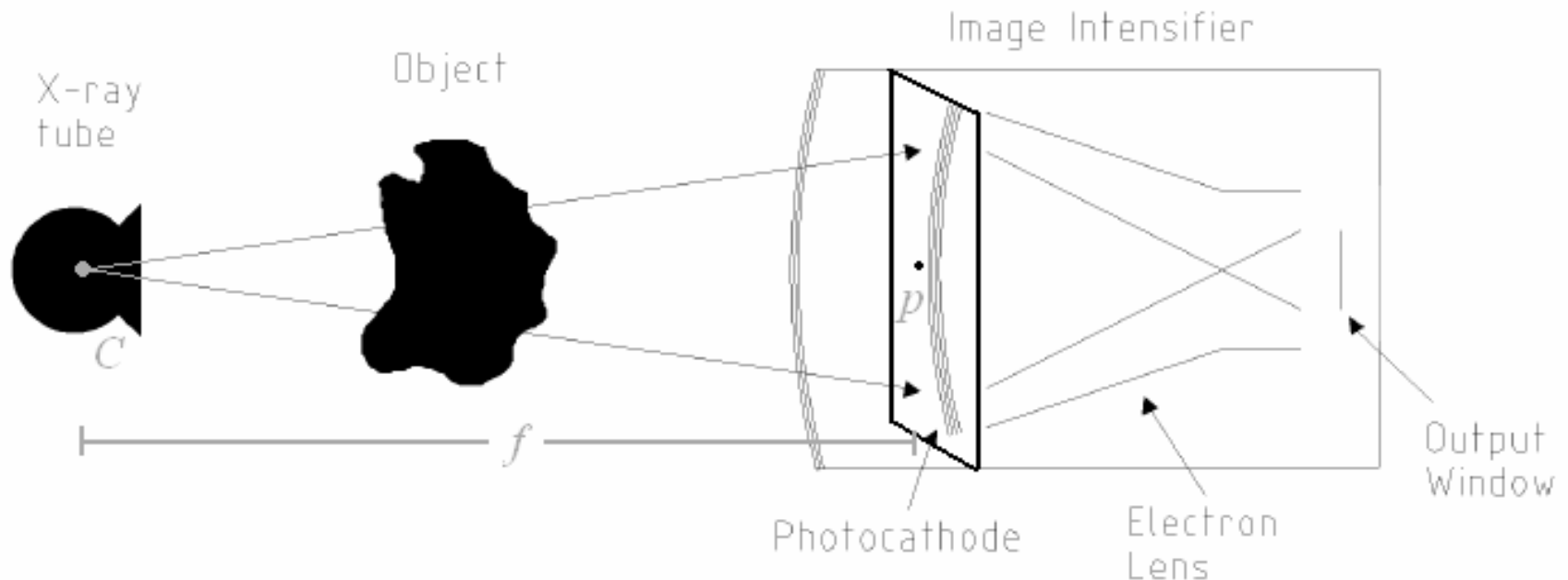
[Boykov, Y., Jolly, M.P.: **Interactive organ segmentation using graph cuts**, MICCAI 2000, Lecture Notes in Computer Science, vol. 1935, pp. 276–286.]

One-Click Aorta Segmentation Demo




Intra-operative 2D/3D Registration

- Automatic segmentation of the fiducials in 3D (CT) and 2D (X-ray)
- C-arm projection matrix estimation by DLT (direct linear transformation) using the 2D-3D point correspondencies



Distortion during Fluoroscopy


- pincushion distortion → due to the curved X-ray detector
- spiral distortion → due to the earth's magnetic field



(distorted)

Distortion-Correction

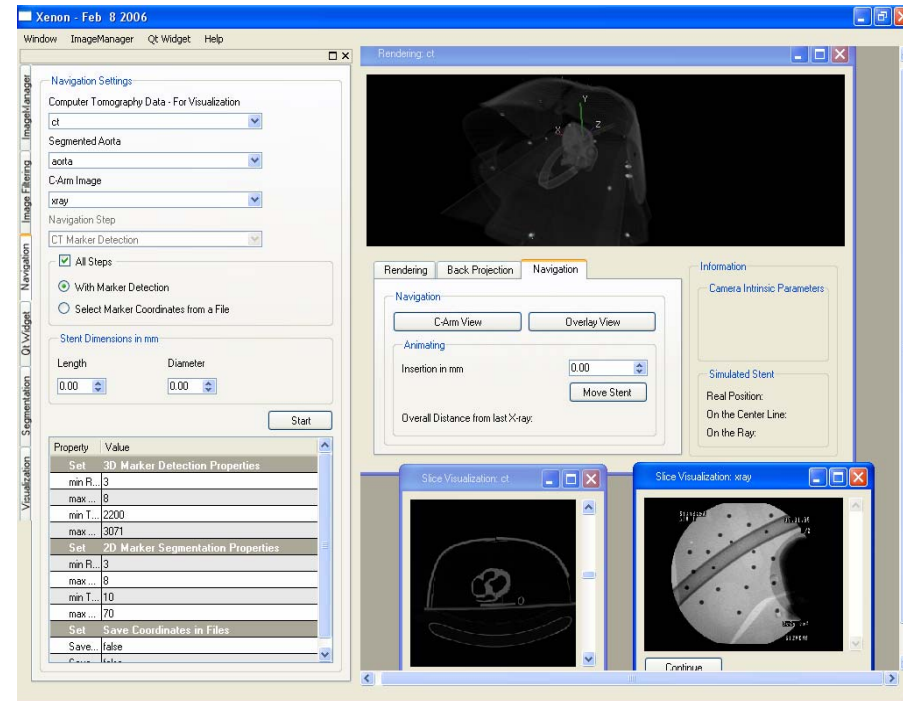
- Lookup tables



(undistorted)


Intra-operative Visualization

- Visualization of the current stent position in the CT volume at the right position, based on its predefined length and diameter
- Update of the current stent position in the aorta
- Visual overlay of the two image modalities



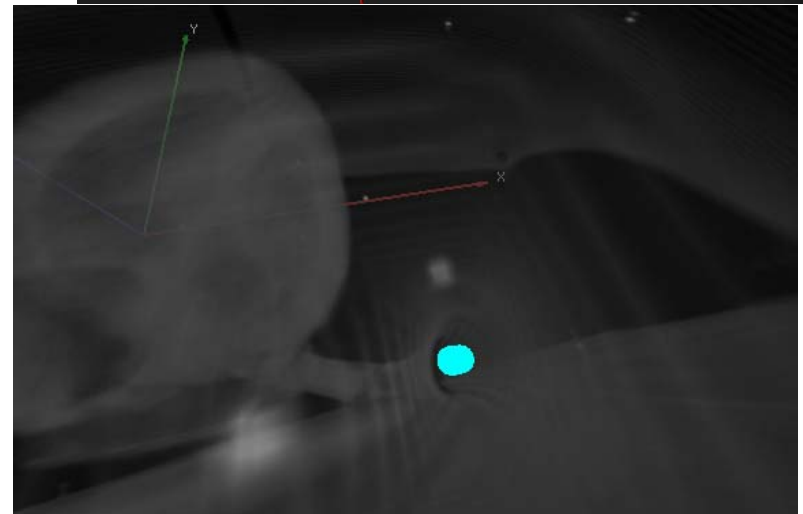
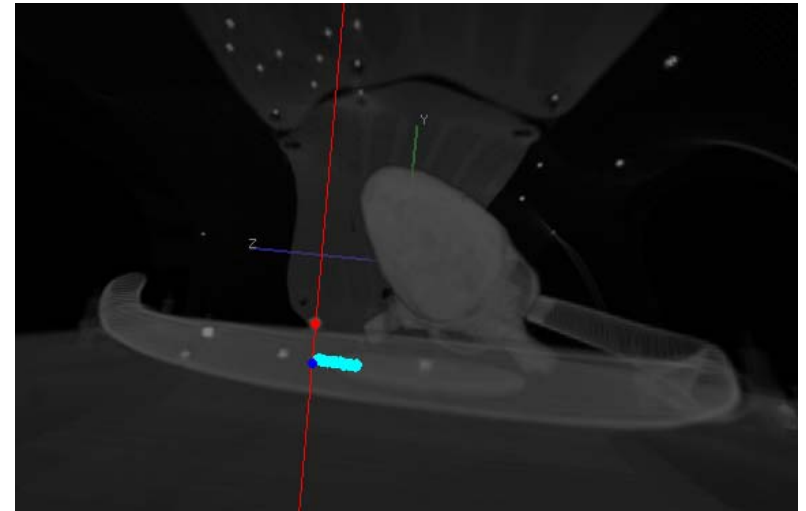
Visualization – Centerline Representation

- Stent assumed to be always in the aorta, on its centerline



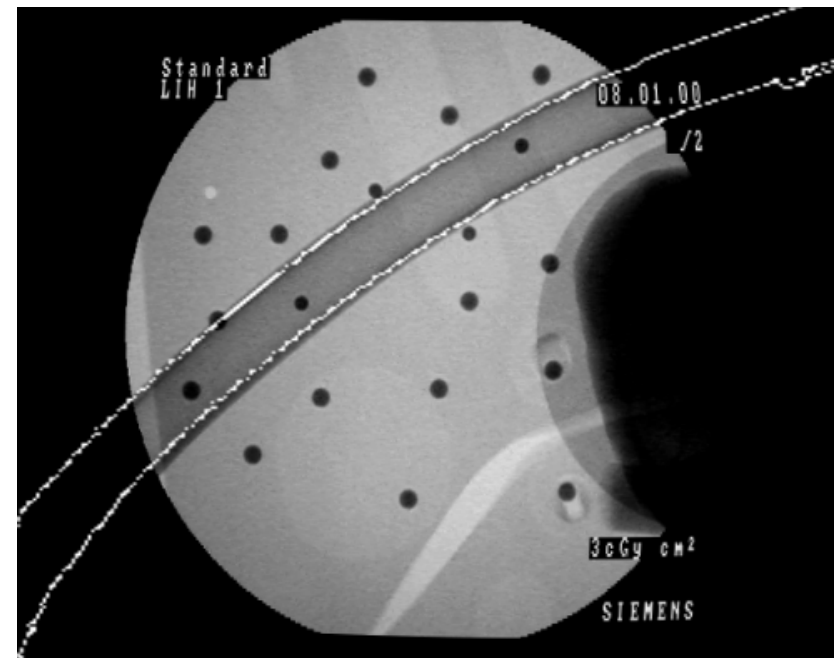
Visualization – Spatial Position Recovery of the Stent

- Determination of the 3D position of the stent from its projection in the X-ray image
 - Interactive selection of the 2D stent position (e.g. with the mouse)
 - Back projection - definition of a ray of sight
 - Determination of the closest point of the centerline to this ray



Visualization – Overlay

- Initialization of the CT volume with the previously determined projection geometry of the C-arm
- Acquisition of an artificial X-ray (DRR) of the CT volume
- Visual overlay of the DRR with the X-ray image
- Aorta visible in the next X-ray image without additional contrast agent application

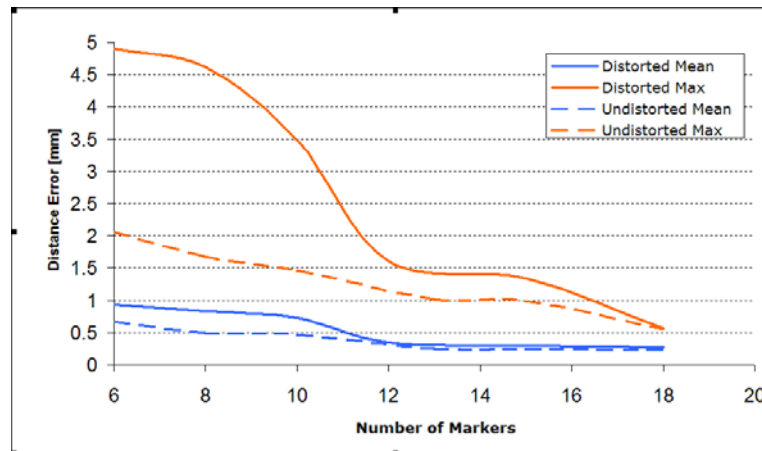


Visualization – Update of the Stent's Position

- Surgeon inserts or withdraws the catheter (e.g., a measure tape gives the distance of the insertion depth)
- Input of the inserted distance into the navigation system
- Update of the current stent position → animation of the stent towards the desired position

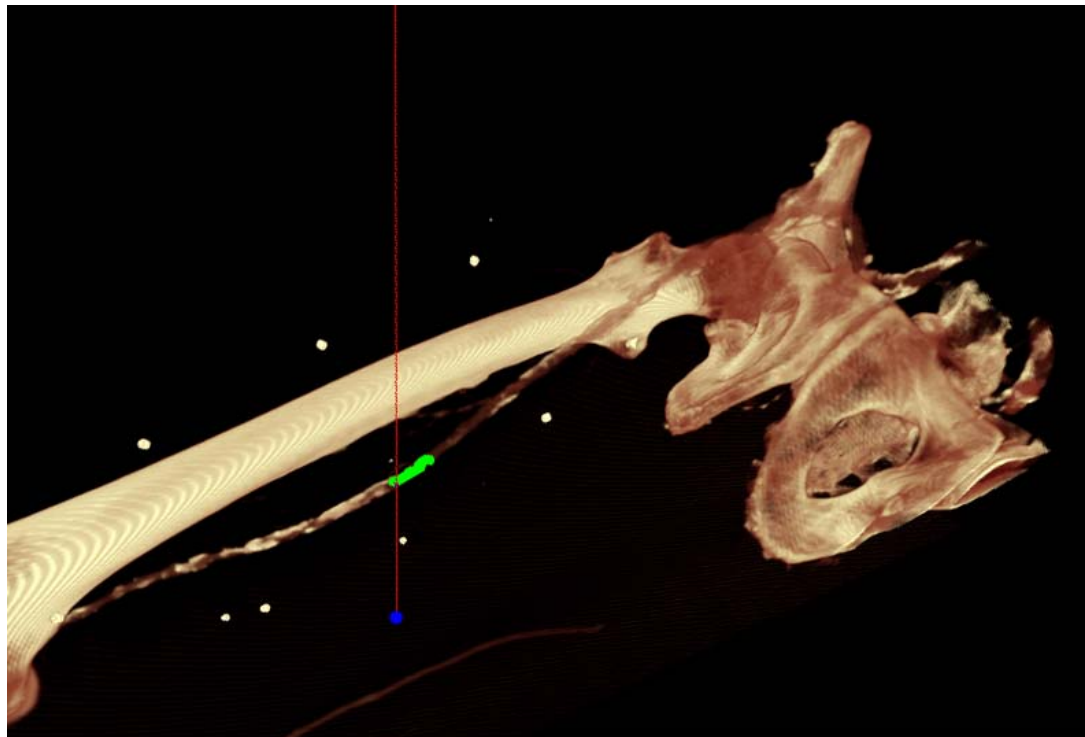
Results

- Successful automatic segmentation of the aorta for 4 CTA data sets of real patients – more to come
- Evaluation of distorted and undistorted images → undistorted images give better results
- Usually, at least ten spot correspondences are needed for sub-millimeter accuracy
- Back projection of the stent in the aorta in sub-millimeter area



Patient Study

- Endovascular intervention for the treatment of the stenosis of the femoral artery using a balloon-catheter system (mainly rigid)



Conclusion/Discussion

- Rapid pre-operative aorta segmentation with only one seed point
- Accurate intra-operative navigation and placement of the stent is anticipated
- Via 3D information, a reduction of the number of X-ray acquisitions under angiography is anticipated
- Via overlaying the image data, reduction of the amount of contrast agent injection is anticipated
- Needs to be validated for the more deformable aortic arch
- Automatization → a single intra-operative interaction step (stent 2D localization)
- Simple system integration → only a PC and CT-visible fiducials are required
- Fiducial-based approach may require new protocols to ensure the fiducials to have the same pre- and intra-operative position!