

Interdisciplinary Project (Biology) – Final Report

# MR-based Attenuation Correction for PET

Loren Arthur Schwarz

7th August 2006

Chair for Computer Aided Medical Procedures,  
Nuclear Medicine Department of the Klinikum rechts der Isar,  
Chair for Animal Breeding  
Technische Universität München

**Advisors:** Prof. Dr. Nassir Navab, Prof. Dr. Hans-Rudolf Fries, Dr. Marc Huisman  
**Supervision:** Andreas Keil  
**Period:** March 01, 2006 – August 01, 2006

# Contents

<b>1</b>	<b>Introduction</b>	<b>3</b>
<b>2</b>	<b>Background</b>	<b>3</b>
2.1	Positron Emission Tomography . . . . .	3
2.2	Attenuation Correction . . . . .	4
<b>3</b>	<b>Project Description</b>	<b>5</b>
3.1	Previous Work at CAMP . . . . .	6
3.2	Work Accomplished in this Project . . . . .	6
<b>4</b>	<b>Results</b>	<b>7</b>
4.1	Small Animal Imaging . . . . .	7
4.2	Implemented Software Module . . . . .	9
4.3	Evaluation of MR-based Attenuation Maps . . . . .	9
<b>5</b>	<b>Conclusion</b>	<b>11</b>
5.1	Summary . . . . .	11
5.2	Faced Issues . . . . .	12
5.3	Future Work . . . . .	13
<b>6</b>	<b>References</b>	<b>14</b>

# 1 Introduction

Positron Emission Tomography (PET) is an important medical imaging modality that can provide an insight into the function of many human and animal organs. While in other modalities, such as Computed Tomography (CT) and Magnetic Resonance Imaging (MRI), mainly anatomical structures are visible, PET images show biochemical and physiological activity. There are many fields of application for PET imaging which range from oncology to the analysis of body metabolism. Examination of small animals, such as mice and rats, is of great importance to biologists and to the pharmaceutical industry, where pre-clinical experiments are performed on small animals.

A crucial issue related to PET is the so-called attenuation effect that is inherently caused by the physics underlying PET technology. Without attenuation correction, PET scans appear blurry and have low contrast.

Attenuation correction relies on prior knowledge about attenuation properties of different tissue types. If it is known which tissues are being scanned by a PET system, the resulting image can be corrected. One common way to perform attenuation correction is to combine a PET scan with a CT scan. The two data sets are spatially registered and attenuation values for every single voxel are calculated from the CT image. These attenuation coefficients (or  $\mu$  values) are stored in a so-called attenuation map (or  $\mu$  map) which can then be used as an input to correct a PET image.

Mainly because of the side-effects of X-rays in CT technology that are harmful to animals and humans, there is a great interest in using MRI technology for attenuation correction. The aim of this interdisciplinary project (IDP) is to evaluate approaches for attenuation map generation from MR images. Initially small animal scans are used for experiments and finally also human clinical data sets are taken into account.

## 2 Background

The following paragraphs give a short introduction to the background that is necessary to understand the procedures of this project. After a brief description of the principles of PET imaging, the attenuation effect – focus of this project – is illustrated in more detail.

### 2.1 Positron Emission Tomography

All medical imaging technologies that share the term “tomography” have in common that three-dimensional, volumetric data sets are generated after scanning a patient. While CT is based on X-rays that are attenuated while they pass through the subject, the reaction of atoms to a strong magnetic field is measured in MR imaging. However, both CT and MRI share the property that the examined subject is imaged on a structural level; anatomy is made visible. Bone is clearly imaged in CT and organs in MR scans, but there is hardly a hint about functional processes taking place inside the body.

PET is the opposite technology to CT and MR in that no anatomical structures but body functions are visualized. A radioactive tracer is injected into the patient and spreads across the body. Its decay is measured from outside the patient, allowing to compute its position

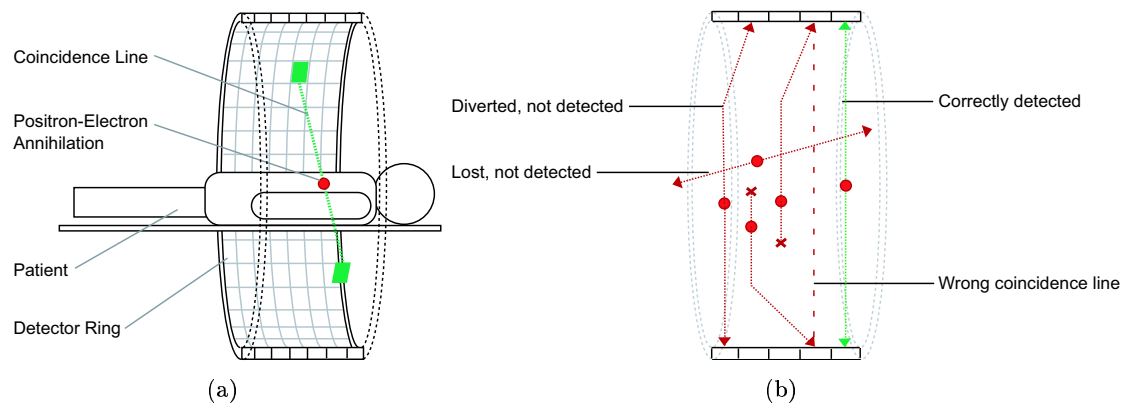


Figure 1: (a) The basic principle of PET. Two photons emitted to opposite directions at  $180^\circ$  after an annihilation event of a positron with an electron. (b) Possible effects of attenuation on the detection of photons on coincidence lines.

inside the body. Such tracers are pharmaceuticals containing radioactive isotopes of fluor, carbon, oxygen or nitrogen that are integrated into common organic molecules. An organism cannot distinguish these modified molecules from their non-radioactive counterparts and uses them in its regular metabolism.

In FDG-PET, a widely-used form of PET examination,  $^{18}\text{F}$ -Fluor-Deoxyglucose (FDG) is used as a tracer. It is acquired by the body like glucose, but it cannot be metabolized any more past a certain step. The substance is therefore accumulated in cells and can give a hint on the level of glucose metabolism in certain body regions. Cancerous tissue, for example, typically has an increased glucose metabolism and will therefore accumulate larger amounts of FDG.

The radioactive decay of the tracer pharmaceutical causes positrons to be emitted. Every positron reacts with an electron within a very short time frame, resulting in an annihilation of the two particles. Two photons are sent out from the location of the annihilation event and radially move apart in opposed directions at approximately  $180^\circ$ . Special detection crystals arranged in a circular structure around the patient can register arriving photons. If two crystals on the detector ring belonging to a coincidence line through the patient detect a photon within a few nanoseconds, an annihilation event is assumed and its position is estimated. Figure 1.a) illustrates this basic idea. The sum of all registered annihilation events allows reconstruction of cross-section images which, in turn, can be used for 3D visualization.

## 2.2 Attenuation Correction

In practice there is a significant problem in PET imaging that is referred to as the attenuation effect. It is caused by attenuation or diversion of photons by different kinds of tissue that they pass through on their way to the photon detectors. A photon can either be absorbed so that it does not reach a detector crystal at all, or it can be deviated from its original coincidence line so that it is not registered together with the corresponding second photon. In the best case these effects just result in undetected annihilation events.

Otherwise, however, noise is added to the PET image, since photons that have not originated from a single annihilation event can be wrongly assumed to be coincident. In this case the reconstruction yields a wrong coincidence line and the location of the annihilation event is misestimated. A few such possibilities are shown in Figure 1.b).

Since different types of tissue exhibit different attenuation properties, it is helpful to know what types of tissue are being scanned. This additional information can then be used to artificially correct the attenuation effects. In combined PET-CT machines CT scans are used to infer this kind of information. CT technology is especially suited for this task since it is based on the attenuation of X-rays by body tissue. In this context, CT intensities (Hounsfield units) can be thought of as attenuation coefficients at the effective energy of CT. A simple relationship can be established between Hounsfield units and PET attenuation coefficients ( $\mu$  values).

If for various reasons MRI technology is to be used for attenuation correction, then there is no straightforward way of deriving attenuation values. Because of the totally different mechanism of MR scanners, intensities in an MR image cannot be directly mapped to attenuation coefficients. MR scans of even identical anatomical structures can be highly different, depending on which MR sequence – a set of parameters suitable for a certain imaging purpose – is used. For instance, in a CT scan regions with intensities around 1.000 Hounsfield units (HU) can be assumed to be bone, so that a known PET attenuation coefficient can be assigned. In MR scans such assumptions cannot be made.

The general process of MR-based attenuation correction can be summarized as follows:

- Acquire PET and MR scans of one subject.
- Register the MR image to the PET image.
- Segment the MR image and label tissue types (e.g. bone, air, soft tissue).
- Assign pre-defined attenuation coefficients for each tissue type.
- Apply Gaussian smoothing to the MR image.
- Apply PET correction algorithm to PET image using attenuation map.

From a technical point of view, an attenuation map is a volumetric data set similar to a CT or MR scan where every voxel contains an attenuation coefficient for the corresponding spatial location. PET scanner software typically includes a possibility to supply an attenuation map for correction that was generated externally, i.e. not by means of a PET transmission scan.

### 3 Project Description

An interdisciplinary project (IDP) is supposed to offer an insight into a field of application for computer science. Several IDPs have already been accomplished at the Chair for Computer Aided Medical Procedures (CAMP) on the topic of MR-based attenuation correction. The purpose of the following sections is to give an overview of previous work and to clearly state the goals of this project.

### 3.1 Previous Work at CAMP

The results of previous work on MR-based attenuation correction that this project builds upon are mainly the following. Experiments with phantom objects have been performed in order to get started with PET and MR image acquisition. The fundamental issue of registration has been successfully addressed resulting in an application framework called “MAPFusion”. This program allows 3D-3D registration of MR scans to PET images using various settings. Mutual Information (MI) proved to be the most general and powerful similarity measure for registration. Furthermore, several suitable segmentation approaches for MR images have been identified, most notably the joint histogram approach. A more detailed evaluation of segmentation algorithms has not been performed. The first step towards real-world application of the aforementioned results was to do small animal experiments. Several MR, CT and PET datasets of mice have been acquired. Due to the fact that MR scanners built for human applications were used, the resulting data sets were of very low spatial resolution and could not be used for this project.

### 3.2 Work Accomplished in this Project

The outcome of this project was not foreseeable in its entirety from the beginning. The main goals were on the one hand to acquire new small animal data sets using newly available PET and MR scanners with improved quality. Segmentation approaches should be evaluated with respect to the new data sets. On the other hand, a software module should be developed implementing one approach for MR-based  $\mu$  map generation.

The procedures completed include the following:

**MR scans of mice in several sequences.** The initial step was to perform MR scans of mice in order to find out what level of detail can be achieved with the new MR scanner. A special small animal coil was used in combination with a Philips human MR scanner. All data sets were evaluated with respect to how suited they are for attenuation map generation.

**Acquisition of a whole PET-CT-MR data set.** In order to extend small animal experiments, the idea was to compare attenuation maps obtained from a CT scan with newly generated MR-based attenuation maps. Due to technical problems with the PET and CT scanners this task could not be completely accomplished. However, another set of MR scans was performed, this time using a conventional human wrist coil instead of the specialized small animal coil. Image quality was not distinguishable between the two acquisition modes.

**Software Implementation.** A software module was implemented for practical use with further small animal experiments. It enables researchers to generate attenuation maps from MR images which can then be exported in a data format suitable for the microPET small animal PET scanner.

**Problem discussion.** Segmenting more than two classes from small animal MR scans proved to be hardly feasible. The decisive question became to evaluate how important a more advanced segmentation is in practice. In other words: would there

be a significant negative influence on PET image correction, if an attenuation map was used that does not distinguish between soft tissue and bone?

**Work on human clinical data.** The final step was to evaluate to which extent the results from small animal imaging apply to human clinical data. A twofold approach was pursued in order to assess the quality of attenuation maps that can be obtained by binary segmentation. On the one hand, CT-based attenuation maps were examined to find out how detailed an attenuation map should be for practical use. On the other hand, a comparison of CT-based and MR-based attenuation maps was performed.

## 4 Results

The following sections aim to give a more detailed picture of the results that have been achieved in this project. The sections are ordered to reflect the temporal structure of the project.

### 4.1 Small Animal Imaging

The best isotropic resolution that could be achieved with the new Philips human MR scanner was  $0.2 \times 0.2 \times 0.2$  cm. Best results have been obtained using the T1 and T2\* sequences, where the former sequence showed best soft tissue contrast and the latter sequence showed bone structures more clearly (see Figure 2).

Despite the high spatial resolution of the MR mice images, the level of detail showed to be still hardly sufficient for segmentation into more than two classes. The following limiting factors were identified, where some are typical characteristics of MR imaging:

- Different types of tissue can have identical image intensities.
- Identical types of tissue can have different image intensities.
- Image intensities vary strongly between different MR scans.
- Bone structures are tiny, rarely larger than a few voxels, if visible at all.
- Acquisition time for one sequence in the necessary resolution is 25 - 30 minutes.

The first three aspects mean in particular that a simple attribution of certain gray levels to specific tissue types (as it is done for CT images) is not possible. Segmentation techniques such as region growing would hardly yield a segmentation into more than two classes, because of the small details in mouse scans. The joint histogram approach (JH) is also not feasible for similar reasons. Furthermore, the long acquisition time makes taking more than one MR sequence (as needed for JH) almost impossible in practice. Anaesthetizing mice for such long periods of time showed to be difficult and dangerous for the mice.

The only feasible approach without using advanced techniques, such as atlas based registration, seems to be a simple binary segmentation into air and tissue. In fact, attenuation maps generated from MR scans using this simple segmentation approach proved to be better than what is achievable using a PET transmission scan for small animals.

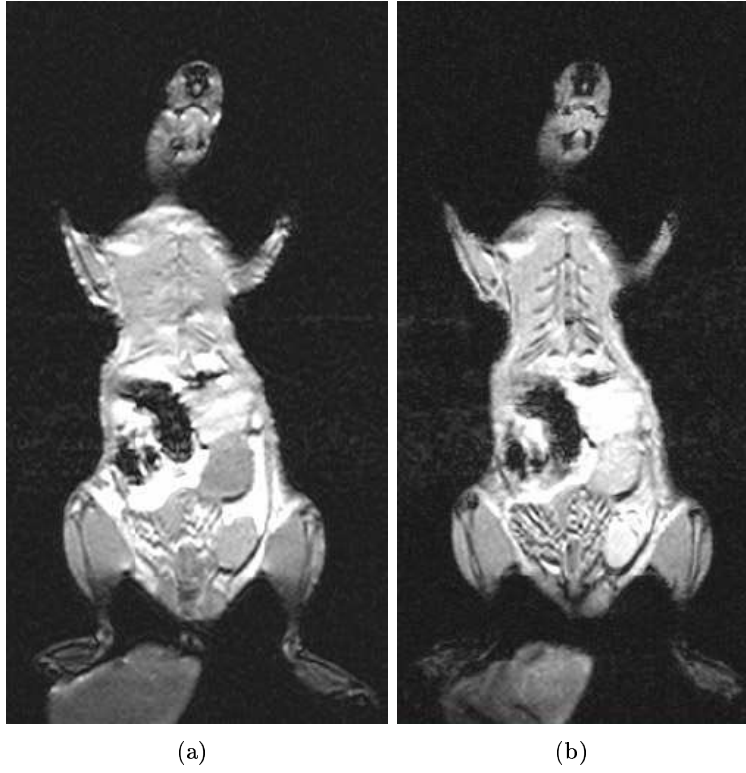


Figure 2: Sample coronal slices through two MR scans of the same mouse. (a) T1 weighted, (b) T2\* weighted.

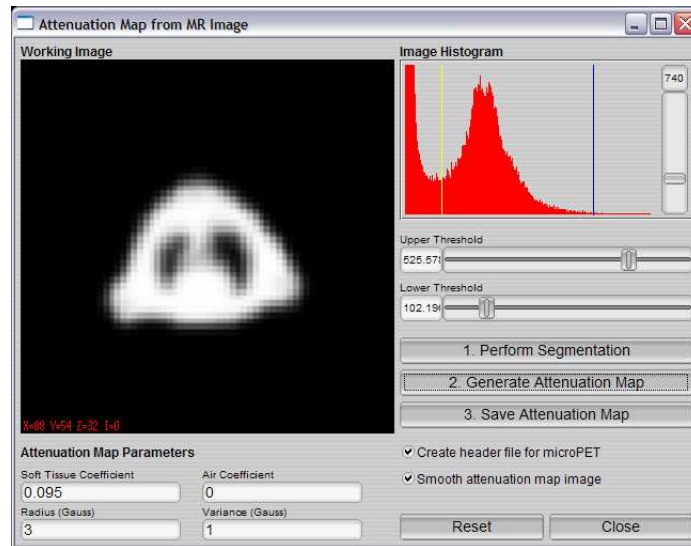


Figure 3: The software module implemented as an addition to “MAPFusion”, the PET-MR registration framework.

## 4.2 Implemented Software Module

Thanks to the existing PET-MR registration framework “MAPFusion”, the implementation of an attenuation map generation module was simple. Based on FLTK, a cross-platform library for graphical user interfaces, and the CAMPlib, a collection of tools for use in medical imaging, the module was programmed in C++. It can be accessed in MAPFusion after an MR image has been registered to a PET image. In addition there is also a module to generate attenuation maps from CT images using the standard linear transformation. This module is helpful for comparison of CT-based and MR-based attenuation maps.

The new dialog for  $\mu$  map generation from MR scans is displayed in Figure 3. The image on the left side shows the volume data set which can be browsed by rotating the mouse wheel. After selecting the upper and lower threshold using the image histogram, image regions with intensities between the two thresholds are segmented against the background. Foreground voxels are then assigned the attenuation coefficient for tissue, the background is treated as air. The pre-defined  $\mu$  values of  $0.095\text{ cm}^{-1}$  for soft tissue and  $0.0\text{ cm}^{-1}$  for air can also be changed by the user.

As a last step the algorithm performs Gaussian smoothing on the binary attenuation map. This is on the one hand necessary to match the resolution of the MR scan to that of typical  $\mu$  maps, which is much lower, e.g.  $128 \times 128 \times 64$  pixels. On the other hand, after Gaussian smoothing the attenuation map contains more than just the two  $\mu$  values for tissue and air and therefore yields a better approximation of CT-based attenuation maps or PET transmission scans.

An export function has been implemented that allows to save the generated attenuation map in the format required by the Concorde microPET small animal scanner which is used at the nuclear medicine department of Klinikum rechts der Isar. This file format consists of a raw data file containing the image intensities as 4-byte floating point numbers and a special ASCII header file with information about the attenuation map.

## 4.3 Evaluation of MR-based Attenuation Maps

As has already been stated in earlier sections, segmentation of small animal MR scans into more than two classes turned out to be hardly feasible. However, since this does not seem to be a limitation for small animal imaging, the focus was shifted towards human clinical data. The aim was to find out whether also in human PET imaging an attenuation map based on two classes can be sufficient. The answer to this question is of great interest before starting to investigate more sophisticated MR image segmentation approaches.

Existing data sets of two patients were used for experimentation, namely a whole-body MR scan and a PET-CT data set for each patient. The advantage of not having to perform new scans was unfortunately at least partially outweighed. As there was no intention to perform registration experiments on the images at the time they were acquired, the patient position varies strongly between the data sets. Moreover, the whole-body MR scans were taken at a relatively low coronal resolution of only 25 slices. Nevertheless, a few regions of overlap between the MR and CT data sets have been extracted. The following paragraphs refer to one thorax segment that seemed especially suitable for these experiments since many different classes are present in that region (bone, fat, air, lung tissue, blood, etc.).

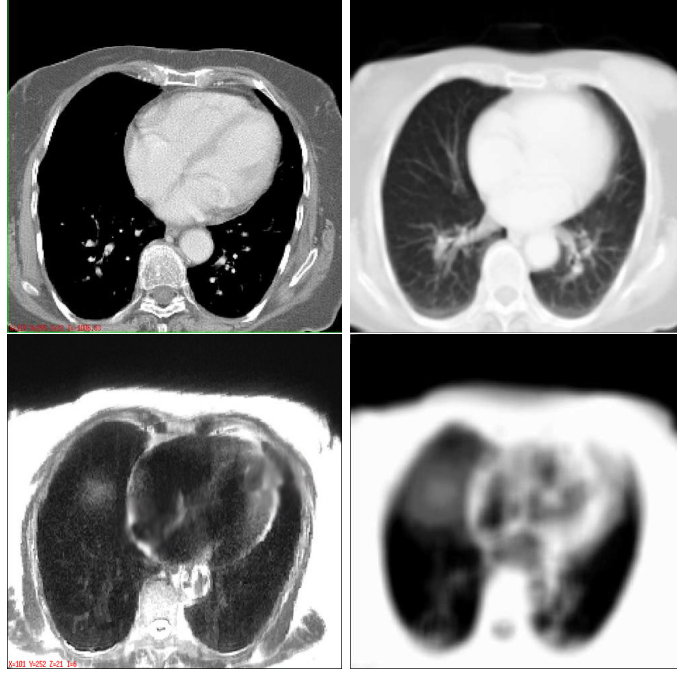


Figure 4: Top row: Sample thorax CT slice (left) and attenuation map obtained by scaling Hounsfield units to  $\mu$  values (right). Bottom row: Sample MR slice of same patient (left) and attenuation map generated by binary thresholding (right).

The left hand side of Figure 4 shows corresponding slices of the CT and MR data sets. On the right hand side the attenuation maps generated from these images can be seen. The MR-based attenuation map was obtained using the binary thresholding technique. A simple scaling function that maps CT Hounsfield units to PET  $\mu$  values was used to generate the CT-based  $\mu$  map. This transfer function was described in detail in [4] and is essentially the following equation:

$$\mu = \begin{cases} (9.5 \times 10^{-5}) \times (HU + 1000), & \text{if } HU < \tau \\ a \times (HU + 1000) + b, & \text{if } HU \geq \tau \end{cases}$$

Where HU is a given CT value in Hounsfield units, a and b are preset parameters depending on the CT tube voltage used for the CT scan.  $\tau$  is a breaking point that corresponds to the transition from soft tissue to bone (typically at values around 70 HU). Since intensities in CT images have a very large range ( $-1.000$  to  $3.096$ ),  $\mu$  values tend to be overestimated in CT-based attenuation maps. Especially the values for bone, which are only slightly above those of soft tissue in PET transmission scans, are typically too high in CT-based attenuation maps. The above formula was intended to decrease this effect.

Generation of the MR-based attenuation map revealed the probably most severe issue related to the binary thresholding approach: Setting the segmentation threshold involves finding a difficult compromise. As can be seen in the sample MR image in the bottom row of Figure 4, the heart is hypointense due to quickly moving blood. This means in particular that a clear segmentation of the heart will never be possible and the  $\mu$  map will not look like the CT-based  $\mu$  map, where the heart is clearly visible.

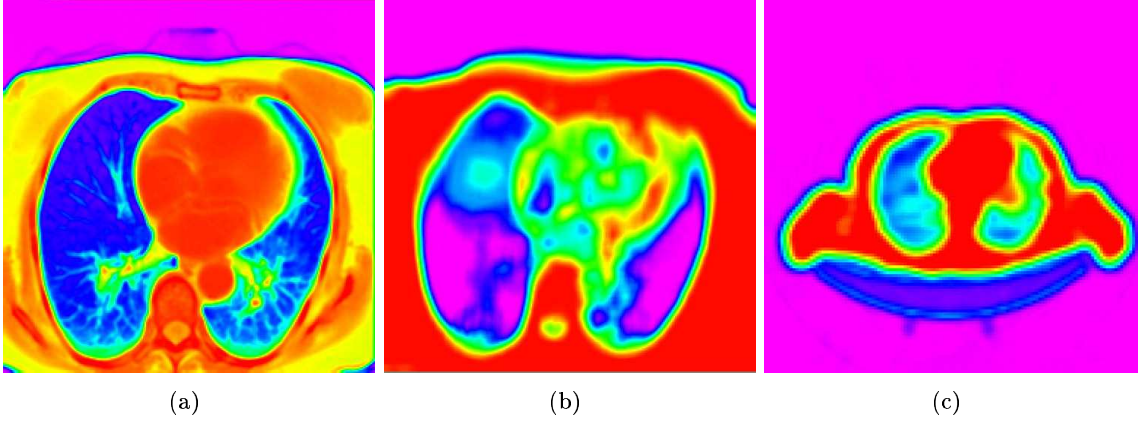


Figure 5: Colored visualization of different attenuation maps. (a) CT-based attenuation map, (b) MR-based attenuation map of same patient, (c) PET transmission scan of different patient.

A more precise evaluation of the differences between the CT-based and MR-based attenuation maps can be deduced from Figure 5. The colors are stretched over the whole range of intensities of the attenuation maps, where blue corresponds to low values and red to high values. The CT-based attenuation map is more detailed but the variation of values in the soft tissue regions around the lungs is relatively small. While the corresponding (red) regions in the MR-based  $\mu$  map have a constant value of 0.095, the values vary between 0.082 and 0.110 in the CT-based  $\mu$  map. Whether this variation is of advantage for PET attenuation correction or if such a level of detail is an overestimation resulting from the nature of CT images, has to be clarified in further experiments.

The transmission scan shown in Figure 5.c) partly justifies the claim that the simple segmentation-based  $\mu$  map generated from an MR scan can be sufficient for attenuation correction. PET transmission scans can be thought of as the Gold standard attenuation maps, since by construction they quantify the attenuation of photons at the effective PET energy. Although the displayed transmission scan shows a different patient, it is clearly visible that there is hardly any distinction between tissue types. In fact, no bone structures can be seen at all. However, the heart is assigned soft tissue  $\mu$  values, what is not the case in the MR-based attenuation map.

## 5 Conclusion

Results and several general issues faced during the work on this project are summarized in the following sections. Finally, ideas for possible future work are outlined.

### 5.1 Summary

Attenuation correction is a crucial aspect related to PET imaging. Many research groups currently focus on developing combined PET-MR scanners to overcome disadvantages of PET-CT machines resulting from the use of harmful X-rays. However, the derivation of an

attenuation map from MR scans is not as straightforward as the general transformation of Hounsfield units in CT images to  $\mu$  values. A simple approach to MR-based attenuation map generation has been devised and evaluated using several small animal and human MR scans. Applying a threshold to the MR image yields a segmentation into two classes, e.g. soft tissue and air. Known PET attenuation coefficients for these two types of substance can be assigned to the segmented regions.

The obtained  $\mu$  maps showed to be sufficient for small animal imaging, since attenuation effects that are not captured by the simple  $\mu$  map are negligible for small subjects such as mice. While attenuation maps created from human MR data generally show a lower level of detail than CT-based attenuation maps, the resolution of MR-based  $\mu$  maps is still higher than that of PET transmission scans. The most critical aspect of the segmentation-based approach is to find a suitable threshold value that best separates two classes of substance, e.g. soft tissue and air. The remaining question is whether the quality of  $\mu$  maps achievable using the binary segmentation approach is sufficient for practical use in clinical PET applications.

## 5.2 Faced Issues

Aside from general problems related to algorithm design and application implementation, the issues faced during this project were mainly related to technical and organizational aspects. Since many experts of various fields were involved, efficient planning played a crucial role. Getting experts together for meetings is difficult due to tight time schedules but it is critical for a project's success. If certain knowledge is not accessible at a specific meeting, it is possible that duplicate work is done and decisions are made twice. However, apart from a few minor coordination difficulties, there were no severe problems of this type.

Working together with experts from different domains also includes communication issues. Specific habits can be usual in one scientific discipline but unfamiliar in another one. Precisely articulating requirements and assumptions can help to prevent misunderstandings on both sides. For instance, medical staff responsible for controlling the MR scanner are used to physicists' preferences in MR imaging. These are driven by diagnostic needs and favor a high resolution per slice over a high number of axial slices to increase examination speed. For being valuable in the MR-based attenuation map project, MR scans were expected have a resolution that is as isotropic as possible. This requirement had to be stated several times in order to be fulfilled, as it was opposed to common practice.

Another source of issues was related to small animal imaging in general. Getting access to several mice for scanning experiments proved to be more difficult than expected. One approach was to combine MR image acquisition with another research team working on surgical experiments. Due to seemingly little but still significant differences in imaging requirements between the two teams this approach was discontinued after the initial scanning session. Animal anaesthesia was a reason for a few further problems. Isoflurane-based anaesthesia was initially planned due to its ability to keep a mouse asleep for an amount of time that allows to perform several subsequent MR scans. However, the supply of Isoflurane could not be delivered to the MR scanning facility due to attached metal parts. An alternative anaesthesia provided by manual injection had the disadvantage of only being effective for approximately 30 minutes, the time of a single MR scan. Extending this time frame by means of a second injection showed to be of high danger to the mouse's life.

### 5.3 Future Work

Future work in the field of MR-based attenuation correction that is based on results of this project should include the following aspects that seem worthwhile from the current point of view:

**Experimental evaluation of MR-based attenuation maps.** Attenuation maps generated using binary thresholding should be evaluated in a quantitative way by means of practical experiments using human clinical data. The results of attenuation correction on a sample PET image using MR-based, CT-based and transmission scan-based attenuation maps should be compared.

**Assessment of need for advanced segmentation.** Depending on the results of practical experiments the necessity to develop more sophisticated segmentation approaches should be evaluated. Limitations of practical PET-MR implementations should be kept in mind, for instance the time needed to acquire an MR scan of sufficient resolution.

**Evaluation of more sophisticated techniques.** If practical experiments with human data sets show that segmenting an MR scan into two classes generates attenuation maps of inferior quality, other approaches, such as joint histograms based on several MR sequences, should be reconsidered. Atlas-based techniques for segmentation also seem promising, especially for specific types of clinical applications such as head and skull or thorax examinations.

## 6 References

- [1] Zaidi, H., Montandon, M.-L., Slosman, D.: Magnetic Resonance Imaging-guided Attenuation and Scatter Corrections in Three-dimensional Brain Positron Emission Tomography, *Med. Phys.*, Volume 30, pp. 937-948; 2003
- [2] Zaidi, H. and Hsegawa, B.: Determination of the Attenuation Map in Emission Tomography, *J. Nucl. Med.*, Volume 44, pp. 291-315; 2003
- [3] Chow, P. L. and Rannou, F. R.: Attenuation Correction for Small Animal PET tomographs, *Phys. Med. Biol.*, Volume 50, pp. 1837-1850; 2005
- [4] Rappoport, V., Carney, J. P., Townsend, D. W.: CT Tube-voltage Dependent Attenuation Correction Scheme for PET/CT Scanners, *IEEE*; 2004
- [5] Burger, C. Goerres, G. et al.: PET Attenuation Coefficients from CT Images: Experimental Evaluation of the Transformation of CT into PET 511-keV Attenuation Coefficients, *European Journal of Nuclear Medicine*, Volume 29, pp. 923-927; 2002